



# PJPS

PAKISTAN JOURNAL OF PLASTIC SURGERY

ISSN #: 2307-213X

Volume 13, Issue 02, December 2025

## CONTENTS

### EDITORIAL BOARD PJPS

#### Chief Editor

Mamoon Rashid

#### Editor

Muhammad Mustehsan Bashir

#### Managing Editors

Muhammad Ashraf Ganatra

Ghulam Qadir Fayyaz

Saadia Nosheen Jan

#### Section Editors

Obaidullah

Moazzam Nazir Tarar

Shahab Ghani

Nauman Gill

Mughese Amin

#### Associate Editors:

Shehab Afzal Beg

Naheed Chaudhry

Saeed Ashraf Cheema

#### Assistant Editors

Fahmina Buriro

Safdar Ali Sheikh

#### International Associate Editors

Gulraiz Rauf (UK)

Najeeb Ansari (Oman)

Azhar Iqbal (UK)

Riaz Malik (UK)

Umraz Khan (UK)

Umar Daraz Khan (UK)

Abid Rasheed (UK)

Philip KT Chen (Taiwan)

Muhammad ElShazly (Egypt)

Renato Frietas (Brazil)

Edwar Alvarez (Ecuador)

#### Publication Officer

Moazzam Shahid

#### PJPS Editorial

54

#### Frequency And Pattern of Post Burn Contractures in Children

55

Hira Adil  
Sara Riaz  
Tahmeedullah  
Sumayya Riaz  
Saima Ayub

#### Unveiling the Versatility of Pedicled Thoracodorsal Artery Perforator Flap with a Modified Surgical Technique for Excellent Outcome

61

Muhammad Omar Afzal  
Sadiah Hussain  
Umer Nazir  
Aroobah Iqbal  
Umar Asif  
Hafsa khalid

#### Reconstructive Modalities in the Management of Rhino-Orbito Maxillary Mucormycosis

66

Fatima Askari  
Saad ur Rehman  
Shayan Shahid Ansari  
Rehan Abbas  
Maira Shoaib

#### Comparison of Muscle Sparing Latissimus Dorsi Flap Vs Split Thickness Skin Graft for Post Burn Inframammary Fold Contracture Release in Terms of Contracture Recurrence and Breast Contour

72

Maria Ashraf  
Ammara Rabbani  
Mehwish Ihsan  
Kamran Khalid  
Yawar Sajjad  
Zain ul Abidin

#### Effects of Enteral Albumin on Healing of Laser Doppler Determined Superficial Partial Thickness Fresh Flame Burns of Adults

79

Afzaal Bashir  
Sunaina Afzaal  
Salman Ali  
Hajra Ahmad  
Mohammed A. Alharbi  
Sunniya Afzaal

#### A Terrifying Pediatric Impalement Injury of the Hand

87

Muhammad Imran Khan  
Asthma Sarfaraz  
Hassan Tahir  
Namia Cho

#### Instructions to the Authors

90



## Editorial

### Surgical Training Models – From Apprenticeship to Partnership in Plastic Surgery

Prof. M. Mustehsan, Dr. Sundas

The evolution of surgical education reflects the dynamic tension between tradition and innovation. For much of modern surgical history, the apprenticeship model—where a trainee learned under the close supervision of a master surgeon—defined the path to competence. This system produced generations of skilled surgeons but also carried inherent limitations: variability in training exposure, reliance on individual mentors, and a lack of structured assessment. In today's era of heightened accountability, reduced working hours, and emphasis on patient safety, new models are essential to complement and, in some respects, transform the traditional approach.

Simulation-based training has become the backbone of modern curricula. From simple bench models to sophisticated virtual reality platforms, these tools enable residents to develop technical skills in a safe and reproducible environment. Cadaveric dissections remain invaluable, particularly in specialties like plastic surgery, where millimeter-level precision are critical. Microsurgical training laboratories, using synthetic or animal models, help residents refine fine motor skills before performing high-stakes reconstructions. Likewise, emerging technologies such as three-dimensional printing and augmented reality overlays enable practice on patient-specific models, bridging the gap between simulation and live surgery.

Yet training cannot be reduced to technical competence alone. The culture of surgical mentorship must also evolve. Historically, the “Miyagi model,” where authoritarian leadership and hierarchical control defined the mentor–mentee relationship, although imparts discipline but lacks partnership opportunities with limited holistic development and professional growth of the trainee.

Contemporary residents, particularly in plastic surgery, seek more than rote learning. They value **partnership**, wanting to be engaged as junior team members with active decision-making roles. They expect a **holistic understanding**, where their training encompasses not only operative skills but also wellness, diversity, and balance across professional and personal spheres. Equally important, they desire **opportunities to problem solve**, using their innate creativity and talents to innovate

solutions rather than merely replicate tradition. These shifts in expectation align naturally with the demands of plastic surgery, a specialty that thrives on adaptability, creativity, and individualized solutions for complex problems.

The challenge, then, is to integrate these cultural changes into structured training models. Competency-based progression, from simulators to live surgery, with incorporation of mentorship styles, is the key. For plastic surgery, sequential exposure—beginning with simulation, progressing to supervised autonomy, and culminating in independent practice—must be coupled with mentorship that encourages innovation within safe boundaries.

Resource limitations, particularly in low- and middle-income countries, remain a barrier to widespread adoption of high-fidelity simulation and advanced technologies. Nevertheless, even in resource-constrained environments, cultural change in mentorship is achievable by Simple measures—valuing partnership, promoting holistic well-being, and empowering residents to problem solve.

In conclusion, surgical training is in a period of necessary transformation. Technical models such as simulation, cadaveric dissection, and microsurgical laboratories must be integrated with evolving mentorship paradigms that move beyond authoritarianism toward partnership. Training models that combine structure with creativity, discipline with wellness, and supervision with partnership will ensure that the next generation of surgeons is not only competent but also innovative, resilient, and attuned to the holistic demands of surgical practice.

#### References:

1. Jackson HT, Vaziri K, Bass BL. Surgical Education and Training in the US: a Collaborative Effort to Deliver the Next Generation of Surgeons. *Indian J Surg.* 2022 Apr;84(Suppl 1):183-192. doi: 10.1007/s12262-021-03080-x. Epub 2021 Aug 20. PMID: 34429570; PMCID: PMC8377332.
2. Lubowitz JH, Provencher MT, Brand JC, Rossi MJ. The Apprenticeship Model for Surgical Training Is Inferior. *Arthroscopy.* 2015 Oct;31(10):1847-8. doi: 10.1016/j.arthro.2015.07.014. PMID: 26433232.

## Research Article

### Frequency And Pattern of Post Burn Contractures in Children

Hira Adil<sup>1</sup>, Sara Riaz<sup>2</sup>, Tahmeedullah<sup>3</sup>, Sumayya Riaz<sup>4</sup>, Saima Ayub<sup>5</sup>

<sup>1-3</sup> Burns and plastic surgery center hayatabad, Peshawar, <sup>4</sup> Khyber teaching hospital MTI, Peshawar,

<sup>5</sup> Services Hospital, Lahore

#### Abstract

**Background:** Burn injuries are a global public health concern. Despite timely treatment many patients go on to develop post-burn contractures. Rehabilitation of contractures that are functionally limiting can be challenging.

**Objective:** To determine the frequency and pattern of post burn contractures in children

**Methodology:** This comparative cross-sectional study was conducted at the Department of Plastic Surgery, HMC, over a duration of 6 months. Children diagnosed with post-burn contractures during physical examinations involving limitation of movement were included in the study according to the inclusion and exclusion criteria. A detailed history was taken with special reference to demographic characteristics, duration of burn, and pattern of post-burn contractures and clinical examination of the patients. Data were analyzed using SPSS 23.0 and clinical examination of the patients was carried out at the time of admission

**Results:** The mean age of the patients was 8 years  $\pm 4.04$ . A total of 107(58%) children were male and 78(42%) were female. The frequency of post-burn contractures in children sustaining burn was 39% of all contractures 40% occur in fingers, 28% in wrist and elbow, 22% in axilla, and 10% in ankle/foot.

**Conclusion:** Our study concludes that the frequency of development of post burn contracture after sustaining burn injury in children is quite high and should be an alarm to devise effective policies to prevent and treat it.

**Received** | 08-07-2024 **Revision** | 22-08-2024 **Accepted** | 10-09-2024

**Corresponding Author** | Hira Adil, Burns and plastic surgery center hayatabad Peshawar.

**Email:** h.adil11392@gmail.com

**Keywords** | post-burn contracture, pediatric burns, rehabilitation,

#### Introduction

Burn injuries are a major public health concern worldwide. According to the WHO, the number of deaths resulting from burn injuries is estimated to be 180,000 every year.<sup>1</sup> With advancements in the medical field, there have been significant improvements in the survival of patients with severe burn injuries. Subsequently, rehabilitation for the functionally limiting sequelae after severe burns and social integration of the patient has become an attention-demanding issue. Contractures in the tissues with severe burns are quite common. However, we have limited data of the prevalence of the post burn contractures.<sup>1,2</sup> A study carried out in India showed that the children and infants were the most common

victims of burn injuries with a M:F ratio of 1.3:1.<sup>3</sup> In a recent review, the prevalence of post burn contractures in children was 38- 54%. Another study reported the incidence of post burn contractures to be 23% in pediatric population.<sup>4</sup>

The most common etiological factor for such injuries is flame burns. Involvement of the right hand was observed in 53.33% of patients, with the fingers being the most common anatomical location of the burn (90% of the cases), followed by the wrist and palm.<sup>3</sup> Post burn contractures are responsible for restricting the motion of the affected body part. Data from a study of 1031 patients showed that post-burn contracture was the most commonly affected shoulder joint (27.9%). The

other joints contracted after the burn were the elbow (17.6%), wrist (14.2%), knee (13.3%), and ankle (11.9%).<sup>4</sup> Additionally, these contractures were severely disfiguring, painful, and associated with unacceptable aesthetic results. These contractures limit the daily life activities of the affected patients.<sup>5,6</sup> They often marginalized and encounter considerable difficulties in securing work and acquiring education.<sup>7</sup> The factors responsible for increasing occurrence of contractures include neglect, poverty, delayed treatment, poor initial burn management, lack of well-equipped as well as well-staffed set ups and lack of follow up by the patients.<sup>8</sup> The data from a study suggested that a large percentage (46.67%) of the study patients received initial treatment from paramedics or quacks and only 23.33% of the burn patients received initial treatment from the specialists.<sup>3</sup>

Patients with contractures and disfigurements associated with burn injuries constitute a major portion of the workload of plastic surgeons, particularly in government hospitals. After contracture develops in a burn patient, improvement in the function and aesthetics of the affected part requires surgical management.<sup>9,10,11</sup> To achieve optimal surgical outcomes, proper tissue planning and selection is necessary. Skin shortage is an important problem encountered when dealing with neglected burn contractures. Other factor affecting the surgical management is secondary changes in surrounding tissues like neurovascular structures, tendon, bones and joints and other soft tissues.<sup>2,8</sup>

The aim of this study is to determine the frequency and pattern of post burn contracture in children as no study has ever been published on post burn contractures and its pattern in children in our local population. This study will be shared with the local health care planners to formulate effective strategies for prevention and timely management of post burn contractures of the pediatric burn patients in our local population.

## Methodology

This comparative cross-sectional study was conducted at the Department of Plastic Surgery, Burns & Plastic Surgery Center, for a duration of six months from 17/12/2021 to 17/6/2022. This study aimed to determine the frequency and pattern of post-burn contracture in children and was approved by the institutional ethical review board. Post Burn Contracture (PBC) was defined as contraction of the skin after a second- or third-degree burn, resulting in restriction of movement around the injured area confirmed on

physical examination and clinical history of the patient.

A sample size of 185 was calculated, keeping 38% proportion of post burn contractures in children, with 95% confidence interval, 7% margin of error calculated on WHO formula for sample size determination.

This study included children aged 1–15 years with post-burn contractures in any region of the body. Exclusion criteria, included ongoing acute treatment, individuals older than 15, and lack of parental consent to participate.

Patients visiting the OPD of our hospital with past Hx of burn injury were enrolled according to our inclusion criteria. Parents/guardians of the patients meeting were asked to provide informed consent and were properly briefed about the nature of this study. A detailed history was obtained, and clinical examination of the patients was carried out at the time of admission. Variables such as age, gender, duration since burn, initial treatment, social class, mode of initial burn, site of contracture, frequency, and pattern of post-burn contracture in children were recorded on a predetermined proforma.

Data was entered and analyzed using SPSS Version 23.0. Descriptive statistics were used for analyses. Mean and SDs were calculated for numerical variables, such as age and burn duration. Frequencies and percentages were calculated for categorical variables such as gender, mode of initial burn, site of contracture, social class, initial treatment, incidence, and pattern of post-burn contractures in children. The frequency and pattern of post-burn contractures were stratified by age, gender, mode of initial burn, initial treatment, side of contracture, and social class to observe effect modifications. A post-stratification chi-square test was applied, with P value <0.05 as significant.

## Results

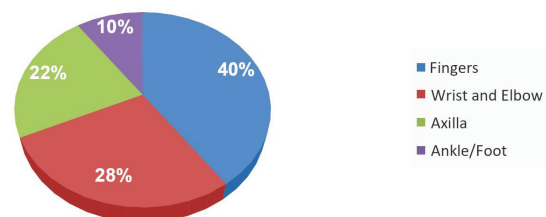
Of 185, 107(58%) children were male and 78(42%) children were female with male to female ratio of 1.4:1. The mean age of the patients was 8 years  $\pm$  4.04. 39(21%) children were age range 1-7 years and 146(79%) children were age range 8-15 years. The duration of burn was stratified on 6 months basis. 65 (35%) children had duration of burn  $\leq$  6 months and 120(65%) children had duration of burn >6 months. 122(66%), 50(27%) and 13(7%) children were from lower, middle and upper class respectively. There were three modes of burn i.e. Flame, scalds and electricity with relative distribution of 68%, 21% and 11% respectively. 56(30%) children

had contracture on left, 61(33%) children had contracture right, 68(37%) children had contracture on both sides. Initial treatment was mostly from General Practitioner i.e. 107(58%). Only 28(15%) children had initial treatment from Burns and Plastic surgery Specialist. There were 72(39%) children who had post burn contracture. There were different patterns of contractures. The frequency distribution of all these variables is given in Table 1.

**Table 1:** Distribution of variables

Sr.No	Variables	Frequency (n)	Percentage (%)
<b>1</b>	<b>Age</b>		
	1-7 years	39	21%
	8-15 years	146	79%
	Total	185	100%
<b>2</b>	<b>Gender</b>		
	Male	107	58%
	Female	78	42%
	Total	185	100%
<b>3</b>	<b>Social Class</b>		
	Lower	122	66%
	Middle	50	27%
	Upper	13	7%
	Total	185	100%
<b>4</b>	<b>Duration of Burn</b>		
	≤ 6 months	65	35%
	> 6 months	120	65%
	Total	185	100%
<b>5</b>	<b>Mode of Initial Burn</b>		
	Flame	126	68%
	Scalds	39	21%
	Electric	20	11%
	Total	185	100%
<b>6</b>	<b>Initial Treatment</b>		
	General Practitioner	107	58%
	Pediatric Surgeon	50	27%
	Burns and Plastic Surgery specialist	28	15%
	Total	185	100%
<b>7</b>	<b>Post-burn Contracture</b>		
	Yes	72	39%
	No	113	61%
	Total	185	100%
<b>8</b>	<b>Pattern of Post-burn Contracture</b>		
	Fingers	29	40%
	Wrist and Elbow	20	28%
	Axilla	16	22%
	Ankle/Foot	7	10%
	Neck	0	0%
	Knee	0	0%
	Groin	0	0%
	Total	72	100%

**Pattern of Post-burn Contracture**



**Fig. Pattern of Post-burn Contracture**

Among 72 children having contractures, 29(40%) children had post burn contracture on fingers, 20(28%) on wrist and elbow, 16(22%) on axilla and 7(10%) on ankle/foot while no patient reported with contracture on knee, groin and neck.

**Table 2:** Stratification Of Post Burn Contracture with respect to other variables

Sr. No.	Variables	Association			
		Yes	No	Total	p-value
<b>1</b>	<b>Age (years)</b>				
	1-7	18(46%)	21(54%)	39(100%)	<b>0.297</b>
	8-15	54(37%)	92(63%)	146(100%)	
	Total	72(39%)	113(61%)	185(100%)	
<b>2</b>	<b>Gender</b>				
	Male	44(41%)	63(59%)	107(100%)	<b>0.472</b>
	Female	28(36%)	50(64%)	78(100%)	
	Total	72(39%)	113(61%)	185(100%)	
<b>3</b>	<b>Social Class</b>				
	Lower	49(40%)	73(60%)	122(100%)	<b>0.478</b>
	Middle	20(40%)	30(60%)	50(100%)	
	Upper	3(23%)	10(77%)	13(100%)	
	Total	72(39%)	113(61%)	185(100%)	
<b>4</b>	<b>Duration of Burn</b>				
	≤ 6 months	27(42%)	38(58%)	65(100%)	<b>0.591</b>
	> 6 months	45(38%)	75(62%)	120(100%)	
	Total	72(39%)	113(61%)	185(100%)	
<b>5</b>	<b>Mode of Initial Burn</b>				
	Flame	50(40%)	76(60%)	126(100%)	<b>0.921</b>
	Scalds	15(38%)	24(62%)	39(100%)	
	Electric	7(35%)	13(65%)	20(100%)	
	Total	72(39%)	113(61%)	185(100%)	
<b>6</b>	<b>Initial Treatment</b>				
	General Practitioner	43(40%)	64(60%)	107(100%)	<b>0.727</b>
	Pediatric Surgeon	20(40%)	30(60%)	50(100%)	
	Burns and Plastic Surgery specialist	9(32%)	19(68%)	28(100%)	
	Total	72(39%)	113(61%)	185(100%)	

Stratification of frequency and patterns of post burn contracture with respect to age, gender, duration of burn, social class, side of contracture, mode of initial burn, initial treatment is given in table 2.

## Discussion

A large number of people are affected by burn injuries every year all over the world. There are approximately 180,000 deaths annually reported in patients experiencing severe burns. However, with the advancements in the fields of plastic and reconstructive surgery, there has been a significant improvement in the prognoses of patients with burn injuries thus reducing the mortality associated with them. Consequently, much of the focus has now been shifted to improve the morbidity in such patients with special attention on rehabilitation, limiting the functional impairment in the affected organs secondary to the post-burn complications and integration of the person into the social machinery.<sup>12,13,14</sup> Post-burn contractures are a prevalent complication in such patients and have a significant impact on the patient's prognosis and morbidity. However, the data about the prevalence of the contracture are scarce.<sup>14</sup>

The results of our study coincided with a recent study conducted by Ekka et al.<sup>15</sup> In this study, the mean age of the patients was 20 years (age of the patients ranging between 1-52 years). This cohort consisted of 5 groups based on their age i.e. 1-10, 11-20, 21-30, 31-40, and >40. The most commonly involved age group was 1-10 which made up 40% of the cohort (24 of 60). Among the most commonly affected were those who predominantly lived at home including preschool children and those adolescents who stayed at home (33.3%). This group was followed by students (30%) and housewives (23.33%). The least affected population included crude and skilled manual workers were the ones least affected (6.67% each). The study found that the most common etiological factor of the burn injuries was flame burn. This has further been discussed and confirmed in another study of India.<sup>16</sup> In 53.33% of the cases, right hand was affected by the burn. On the hands, the most common anatomical sites of burn injury were fingers (involving 90% of patients) that were followed by wrist and palm. In terms of initial management and treatment, only 23.33% of the patients initially received treatment by a specialist while majorities of them (46.67%) received initial treatment by quacks or paramedics.<sup>3</sup>

We observed similar results in another study conducted by Goverman et al.<sup>17</sup> In this study, at least 1 post-burn contracture was developed in 237 (23%) out of 1031 patients at hospital discharge. In these patients, there were an average three (mean = 3.3) contractures per

person. Among the joints, the shoulder joint was the most frequently contracted (27.9%), followed by the elbow (17.6%), wrist (14.2%), knee. The post-burn contractures were divided into mild, moderate or severe. The data suggested that, most of the times, the severity of the contractures was either mild (38.5%) or moderate (36.3%). In terms of the severity of the contracture, the predictors of statistical significance included age of the patient, ICU length of stay, presence of amputation, and black race. While in terms of the number of contractures the statistically significant predictors were total age, length of stay, length of ICU stay, presence of amputation, TBSA burned, and TBSA grafted.<sup>2,14</sup>

Our study is the first to report the epidemiology of post-burn contractures in the pediatric population. The data suggests that about 39% of the children with a major burn injury developed a contracture. Also, the growth of the children further worsens this problem. In such patients, despite the early therapeutic interventions like splinting and positioning, the contractures develop that suggest the need to identify and develop novel and more effective prevention strategies.

The results of our study highlight several key areas for improving clinical practice in managing post-burn contractures in children. With 39% of patients developing contractures, it is essential to implement targeted interventions, particularly for common sites like fingers, wrists, and elbows. The reliance on general practitioners for initial burn treatment indicates a need for enhanced access to specialized care, suggesting that timely referrals to burns and plastic surgery specialists could improve patient outcomes. The high incidence of flame burns points to the importance of strengthening fire safety education, especially for environments where children are at risk. Additionally, the slightly higher prevalence of contractures in lower socioeconomic groups underlines the necessity for targeted resource allocation and community-based interventions. Although factors such as age, gender, and burn duration did not show significant associations with contracture development, further research is needed to explore additional contributing factors. This study's findings should inform local health-care policies and strategies to better prevent and manage post-burn contractures, ultimately improving care for pediatric burn patients.

There are few limitations in our study. It was a single center study with limited targeted population. A multi-center larger study involving a bigger population is recommended for future to know the actual burden of the morbid condition. However, our study will be of help to formulate effective strategies for prevention

and timely management of post burn contractures of the pediatric burn patients in our local population.

### Conclusion:

In conclusion, our research sheds light on the significant issue of post-burn contractures in children, with up-to 1/3 of patients of burn injuries going on to develop contractures. The study highlights the importance of awareness for better prevention and early intervention strategies. The prevalence of flame burns as the main cause also points to the need for more effective fire safety education and preventive measures. Our findings may assist health-care planners in creating targeted approaches to reduce the incidence of post-burn contractures and enhanced care for paediatric burn patients.

**Conflict of interests:** None

**Source of funding:** None

### Author's Contribution

**Dr. Hira Adil:** Conception and design of the study, data collection, analysis and interpretation, Drafting the work Final approval of the version to be published and accountable for all aspects of the work in ensuring that questions related to the accuracy or integrity of any part of the work are appropriately investigated and resolved.

**Dr. Sara Riaz:** Study design, drafting of work, Data Collection and final approval of the version

**Dr. Tahmeedullah:** Conception and design of the study, critical revision of the article and final approval of the article to be published.

**Dr. Sumayya Riaz:** Data collection, Manuscript Revision, analysis and interpretation of data and final approval of the version.

**Dr. Saima Ayub:** Contribution to conception and design of study, Data Interpretation and Analysis and final approval of the version.

### References:

1. Van Baar ME. Epidemiology of Scars & Their Consequences: Burn Scars. 2020 Dec 8. In: Téot L, Mustoe TA, Middelkoop E, Gauglitz GG, editors. Textbook on Scar Management: State of the Art Management and Emerging Technologies [Internet]. Cham (CH): Springer; 2020. Chapter 5. PMID: 36351119.
2. Fanstone R, Price P. Global perspectives on risk factors for major joint burn contractures: A literature review. *Burns*. 2024 Apr;50(3):537-549. doi: 10.1016/j.burns.2023.09.014. Epub 2023 Sep 28. PMID: 37977897.
3. Ekka NMP, Bodra P, Malua S. Pattern of post burn contracture of hand in Eastern India. *J Evol Med Dent Sci*. 2016;5(37):2217-21.
4. Goverman J, Mathews K, Goldstein R, Holavanahalli R, Kowalske K, Esselman P, Gibran N, Suman O, Hershon D, Ryan CM, Schneider JC. Pediatric Contractures in Burn Injury: A Burn Model System National Database Study. *J Burn Care Res*. 2017 Jan/Feb;38(1):e192-e199. doi: 10.1097/BCR.0000000000000341. PMID: 27355656; PMCID: PMC9306192.
5. Hendriks TCC, Botman M, de Haas LEM, Mtui GS, Nuwass EQ, Jaspers MEH, Niemeijer AS, Nieuwenhuis MK, Winters HAH, van Zuijlen PPM. Burn scar contracture release surgery effectively improves functional range of motion, disability and quality of life: A pre/post cohort study with long-term follow-up in a Low- and Middle-Income Country. *Burns*. 2021 Sep; 47(6): 1285-1294. doi: 10.1016/j.burns.2020.12.024. Epub 2021 Jan 7. PMID: 33485727.
6. Oosterwijk AM, Mouton LJ, Akkerman M, Stoop MM, van Baar ME, Scholten-Jaegers SMH, van der Schans CP, Nieuwenhuis MK. Course of prevalence of scar contractures limiting function: A preliminary study in children and adolescents after burns. *Burns*. 2019 Dec;45(8):1810-1818. doi: 10.1016/j.burns.2019.05.003. Epub 2019 Oct 31. PMID: 31676251.
7. Hayashida K, Akita S. Surgical treatment algorithms for post-burn contractures. *Burns Trauma*. 2017 Mar 14; 5:9. doi: 10.1186/s41038-017-0074-z. PMID: 28317000; PMCID: PMC5348756.
8. Ali H, Pervez M, Khyani I, Sami W, Muneeb D. Post-burn neck contracture: effectively managed with supraclavicular artery flap. *Ann Burns Fire Disasters*. 2019 Dec 31;32(4):301-307. PMID: 32431581; PMCID: PMC7197911.
9. Gupta RK, Jindal N, Kamboj K. Neglected post burns contracture of hand in children: Analysis of contributory socio-cultural factors and the impact of neglect on outcome. *J Clin Orthop Trauma*. 2014 Dec;5(4):215-20. doi: 10.1016/j.jcot.2014.07.011. Epub 2014 Aug 19. PMID: 25983501; PMCID: PMC4263997.
10. Sinha I, Zhu D, Ojomo K, Gfrerer L, Sawh-Martinez R, Patel A, Chan RK, Watkins JF. Functional and subjective assessment of burn contracture release in a mission setting. *Burns*. 2016 Mar;42(2):466-70. doi: 10.1016/j.burns.2015.07.009. Epub 2016 Jan 6. PMID: 26778704.
11. Saaq M, Zaib S, Ahmad S. The menace of post-burn contractures: a developing country's perspective. *Ann Burns Fire Disasters*. 2012 Sep 30;25(3):152-8. PMID: 23466805; PMCID: PMC3575141.
12. Meng F, Zuo KJ, Amar-Zifkin A, Baird R, Cugno S, Poenaru D. Pediatric burn contractures in low- and lower middle-income countries: A systematic review of causes and factors affecting outcome. *Burns*. 2020 Aug;46(5):993-1004. doi: 10.1016/j.burns.2019.06.001. Epub 2019 Dec 6. PMID: 31813620.

13. Taira BR, Singer AJ, Thode HC Jr, Lee C. Burns in the emergency department: a national perspective. *J Emerg Med.* 2010 Jul;39(1):1-5. doi: 10.1016/j.jemermed. 2008.01.009. Epub 2008 Aug 30. PMID: 18757160.
14. Yelvington M, Godleski M, Lee AF, Goverman J, Parry I, Herndon DN, Suman OE, Kowalske K, Holavanahalli R, Gibran NS, Esselman PC, Ryan CM, Schneider JC. Contracture Severity at Hospital Discharge in Child-ren: A Burn Model System Database Study. *J Burn Care Res.* 2021 May 7;42(3):425-433. doi: 10.1093/jbcr/ iraa169. PMID: 33247583; PMCID: PMC8344380.
15. Gupta AK, Uppal S, Garg R, Gupta A, Pal R. A clinico-epidemiologic study of 892 patients with burn injuries at a tertiary care hospital in Punjab, India. *J Emerg Trauma Shock.* 2011 Jan;4(1):7-11. doi: 10.4103/ 0974- 2700.76820. PMID: 21633560; PMCID: PMC3097584.
16. Goverman J, Mathews K, Goldstein R, Holavanahalli R, Kowalske K, Esselman P, Gibran N, Suman O, Herndon D, Ryan CM, Schneider JC. Pediatric Contractures in Burn Injury: A Burn Model System National Database Study. *J Burn Care Res.* 2017 Jan/Feb;38(1):e192-e1 99. doi: 10.1097/BCR.0000000000000341. PMID: 27355656; PMCID: PMC9306192.

## Research Article

# Unveiling the Versatility of Pedicled Thoracodorsal Artery Perforator Flap with a Modified Surgical Technique for Excellent Outcome

Muhammad Omar Afzal,<sup>1</sup> Sadia Hussain,<sup>2</sup> Umer Nazir,<sup>3</sup> Aroobah Iqbal,<sup>4</sup> Umar Asif,<sup>5</sup> Hafsa khalid<sup>6</sup>

<sup>1-5</sup>Department of Plastic Surgery, Mayo Hospital/King Edward Medical University, Lahore; <sup>6</sup>St. Vincent's University, Dublin

### Abstract

**Background:** The thoracodorsal artery perforator (TDAP) flap has attracted considerable interest in reconstructive surgery owing to its reliable vascular supply and adaptability. It is an excellent fasciocutaneous flap but hasn't gain much acceptance due to variable outcome.

**Objective:** The aim of the study is to analyze the use of the pedicled thoracodorsal artery perforator flap with description of an easy and reproducible technique of flap raising with good outcome.

**Methodology:** This case series was conducted at Plastic Surgery Department, Mayo Hospital Lahore / King Edward Medical University from November, 2022 to November, 2023. Patients requiring coverage of defects on back, shoulder, axilla and chest were included. The antigrade approach was adopted to raise the flap and cover the defect. The patients' demographics, defect characteristics, surgical details, and postoperative outcomes were systematically analyzed. The primary outcomes included flap survival, donor site scarring and functional outcomes of latissimus dorsi muscle.

**Results:** Total 30 patients were included in the study. 5 cases were of inframammary fold contracture, 9 cases of axillary fold contracture, 5 cases were post tumour resection defect tumor and 1 had post traumatic soft tissue defect. Complete flap survival was noted in 29 cases, with partial necrosis in one flap due to venous congestion secondary to hematoma formation. None of the patients developed any scar related complication at donor site. None of the patients developed functional compromise of LD muscle.

**Conclusion:** The antegrade approach is an easy and reproducible technique to raise TDAP flap to reconstruct wide range of defects.

**Received** | 10-07-2024 **Revision** | 01-09-2024 **Accepted** | 04-09-2024

**Corresponding Author** | Dr. Sadia Hussain, Plastic Surgery Department, 4th floor Surgical Tower, Mayo Hospital/King Edward Medical University, Lahore **Email:** sadianazarhussain@yahoo.com

**Keywords** | Thoracodorsal artery perforator (TDAP) flap, IMF contracture, Antegrade Approach.

### Introduction

The use of pedicled thoracodorsal artery perforator flap (TDAP flap) has been well documented in literature for the reconstruction of axillary, breast and back defects. Its advantages include long vascular pedicle, constant flap thickness, wide arc of rotation and minimum donor site morbidity.<sup>1,2,3</sup>

Thoracodorsal artery perforator flap was first documented by Angrigiana et al. as "latissimus dorsi musculocutaneous flap without muscle" in 1995.<sup>4</sup> He along with

Heitmann et al described the anatomical landmarks that were helpful in identifying the perforators.<sup>5</sup>

Preoperative perforator mapping with hand-held Doppler or computed tomography scan can help in locating perforator on which the flap can be islanded.<sup>6,7</sup> however, when more than one perforator is encountered or if there are only minor perforators, then islanding the flap over a single perforator can result in partial flap loss or venous congestion.<sup>7,8</sup> The retrograde approach is also difficult if a small perforator is encountered due

to its oblique course within the muscle and the accompanying nerve, which gives many branches.<sup>9</sup> As computed tomography scan is not feasible in a resource scarce setup to map perforators pre-operatively, so it is safe to adopt a way to address the problem intra operatively by adopting an appropriate surgical technique to prevent such complications.<sup>10,11,12</sup> Hence, there was a need for a better surgical technique to raise this flap safely without much pre-operative planning and with good viability.

The aim of this article is to share our surgical technique which utilizes antegrade dissection to safely raise the thoracodorsal artery perforator flap with functional preservation of latissimus Dorsi.

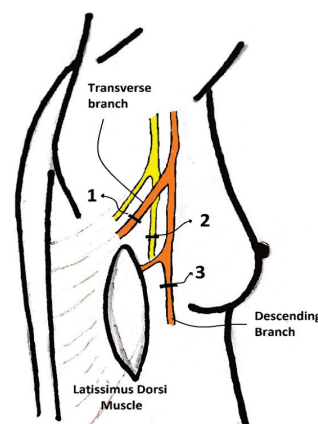
### Methodology

This case series was done at Mayo burn and reconstructive surgery department from November 2022 to November, 2023. After informed consent, patients with either gender between 2 to 60 years of age, who presented with post burn contractures of axilla or inframammary fold, post traumatic defects and defects after resection of malignancy of axilla, anterior or posterior chest wall, scapular and shoulder region, all amenable to reconstruction with TDAP flap were included. Patients with scarring over posterior axillary fold or in whom surgery was done around thoracodorsal arteries and those with uncontrolled co morbidities were excluded. The antegrade approach was adopted to raise the flap and cover the defect. The patients' demographics, defect characteristics, procedural details, and postoperative outcomes were systematically analyzed. The primary outcome measures included flap survival, scar complication, and functional outcome in terms of power of adduction.

### Surgical technique:

Marking of flap was done preoperatively and perforators were marked with the help of hand Held Doppler in sitting position. They were in an area 8 to 12 cm below the axilla and 2 cm medial to the anterior border of latissimus dorsi. Anterior incision was first given, and skin elevated to assess the perforators. After that antegrade dissection was done, thoracodorsal pedicle and nerve were identified and followed by dividing branch to serratus anterior. Source vessels were approached laterally from where they entered the muscle. Muscle was split over the pedicle to identify and isolate the descending and transverse branch of thoracodorsal artery, the latter was ligated and divided. The nerve

accompanying the transverse branch was spared. The descending branch was isolated by further splitting the muscle on over its lateral border until the origin of perforator on which the fascio-cutaneous flap was based.



**Figure 1:** Diagrammatic presentation of the surgical technique. **1:** division of the transverse branch of thoracodorsal arteries. **2:** division of the nerve accompanying the descending branch. **3:** division of the descending branch and accompanying nerve after origin of the perforator.

The descending branch was divided and ligated distal to the origin of the perforator along with the nerve. A small cuff of muscle was also taken along with the perforator, allowing the capture of arborizing vessels for maximum flow. Branch of thoracodorsal nerve accompanying transverse vessels, was spared for preservation of latissimus dorsi function, while the other branch was divided proximally too, to free the source vessel. The flap was then raised from the remaining muscle and donor site is closed primarily in 2 layers. No dissection was done to free the nerve from the perforator, or the portion of descending branch which was taken with the flap. In case if small multiple perforators were encountered, a wider cuff of muscle was taken without further deroofting the perforators. Figure 1 and 2 shows the technique of raising the flap in antegrade fashion.

### Results

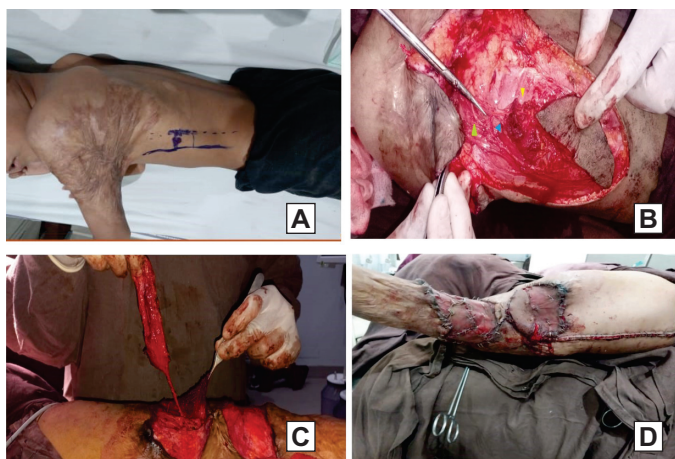
A total of 30 patients were treated with the pedicled thoracodorsal artery perforator flap. The mean age was  $25 \pm 1.5$  years. Majority of the patients were female. There were 15 cases of inframammary fold contracture, 9 cases of axillary fold contracture, 5 underwent soft tissue reconstruction after tumor resection and 1 had post traumatic soft tissue defect reconstructed with TDAP flap (table no.1).

There was complete flap survival in 29 out of 30 (96.7%) cases. There was partial necrosis in one flap due to de-

layed detection of venous congestion, secondary to hematoma formation over the excised scapular border. Stitches were opened and hematoma was evacuated. 60% of the flap was salvaged and rest of the wound was covered with split thickness skin graft after granulation tissue formation. In 23 (76.7%) cases, the flap was islanded on a single perforator, while in 7 (23.3%) cases multiple perforators were found. Mean follow-up period was  $7.2 \pm 1.2$  months. Donor sites were closed primarily in all cases and none of the patients reported hypertrophic scarring or widening of the scar. Latissimus dorsi was found to be functional in all cases, with mean power of adduction  $4.6 \pm 0.1$  according to medical research council (MRC) scale for muscle strength.

**Table 1:** patient demographics & indications of TDAP flap

Patient Demographics:	
Total Patients	30
Mean Age	$25 \pm 1.5$ years
Gender	Cases:
Male	9
Female	21
Indications for TDAP flap:	
Inframammary Fold Contractures	15
Axillary Fold Contractures.	9
Soft Tissue Reconstruction after Tumor Resection	5
Post traumatic Tissue defect.	1



**Figure2:** TDAP flap for reconstruction of soft tissue defect after axillary contracture release. **A)** Marking of the perforators **B)** Dissection through border of trapezius after locating the perforator. Green arrow: Intact nerve along the transverse branch Yellow arrow: Perforator deroofed through the muscle in continuation of the vertical branch Blue arrow: transverse branch White star: divided nerve along the vertical branch of the pedicle. **C)** Fasciocutaneous flap raised **D)** Flap used to cover the roof of axilla along with split thickness skin graft.

## Discussion

Pedicled thoracodorsal artery perforator flap has recently gained popularity in reconstructive surgery. As a pedicled flap it has a wide arc of rotation due to long pedicle to cover regional defects and a thin pliable tissue that matches colors and texture of regional skin.<sup>13</sup> Li et al studied the efficacy of TDAP flap in breast conserving reconstruction of patient with T2 Breast cancer in East Asian population. The authors reported no seroma formation or scar complication and acceptable survival rate, but adopted retrograde dissection aided by pre-operative imaging.<sup>14</sup> They reported wide arc of rotation as we also noted in our case series, allowing breast reconstruction even on the medial pole of the breast. Another article reported good contour formation of the breast after lumpectomy but adopted retrograde approach and raised flaps on single dominant perforators. No detail was provided for raising flaps if multiple perforators were encountered.<sup>15</sup> Nizamoglu et al shared his experience of using TDAP flap salvage surgery in patients going autologous and implant-based breast reconstruction in a single stage procedure<sup>16</sup>. However he emphasized on performing CT angiogram for successful identification of perforator using the retrograde approach which is inconsistent with our experience. Sui et al used TDAP flap for extremity reconstruction and similarly depended on pre-operative CT scans for planning.<sup>17</sup> Thomsen et al described pivot flaps based on thoracodorsal artery for breast reconstruction.<sup>18</sup> They mentioned increased excision of distal 5cm or more of the flap due to inadequate perfusion. Our technique utilizes multiple perforators if a single dominant one is not present, resulting in good outcome. Scafati et al adopted antegrade approach but stressed the identification and islanding of the flap over single perforator.<sup>19</sup> They too stated the occasional absence of a single large perforator but didn't describe improvisation of their technique to solve the issue of multiple small perforators. They utilized preoperative identification of perforators with handheld ultrasound but found that their technique had a steeper learning curve as it required isolation of pedicle from the nerve and its branches.<sup>9</sup> They only described their technique but didn't show the clinical cases to assess the functional outcome of latissimus dorsi flap. We have described the easy antegrade approach with technique to go about the presence of multiple small perforators and shown the clinical outcome with retention of the muscle function in our case series. The perforator-based flap was also shown to be a safe option

with previous history of axillary radiation<sup>20</sup>. To prevent venous congestion, a small cuff of muscle around the perforator was preserved, along with the arborizing vessels, similar to La Padula's technique. However, instead of using a strip of fat tissue for padding, our approach employed a muscle cuff for added protection.<sup>21</sup>

Our study describes an easy and safe method to raise the TDAP flap in 30 patients, yet there are some limitations. The cases were performed by a single author thus the resulting in consistency in the outcome. We selected cases with no scarring over the site of the flap, but in case of supple scar the reliability of the flap is yet to be established. We have taken a vertical skin paddle, but in cases of aesthetically demanding patients a transverse of oblique design is favored. This leaves less room for exploratory technique as we have described. Hence otherwise a safe and easy technique, it is yet to be verified by other surgeons and in other scenarios to cement its utility.

## Conclusion

Antegrade dissection provides a reliable method to raise TDAP flap to cover wide range of defects around axilla. Our improvisation of the technique provides a solution to the presence of multiple minor perforators rather than a single dominant one, when angiography facility is not available.

**Conflict of Interest:** None

**Source of funding:** None

## Author's Contribution

**Dr. Muhammad Omar Afzal:** Conception and design of the study, data analysis and interpretation, agreement to be accountable for all aspects of the work & final approval of the version to be published.

**Dr. Sadia Hussain:** Data analysis, Critical revision of the article, conception and design of the study and final approval of the study.

**Dr. Umer Nazir:** Substantial contribution to acquisition of data, concept and design and final approval of the version to be published.

**Dr. Arooba Iqbal:** Interpretation of data, Critical revision of the article and final approval of the study.

**Dr. Umer Asif:** Interpretation of data Critical, revision of the article and final approval of the study.

**Dr. Hafsa Khalid:** Data analysis and interpretation, concept and design and final approval of the version to be published.

## References

1. Alshahhat O, Autifi M, Hosny M, Osama M, Farid M, Moaty M. Pedicled thoracodorsal artery perforator flap for reconstruction of post burn contracted neck. *Egypt J Hosp*. 2019; 74(5): 1180-5.
2. Qing L, Wu P, Bing Z, Yu F, Pang X, Ding P et al. The concept of the special form perforator flap and its role in the evolution of reconstruction. *J Xiangya Med* 2019; 4:10.
3. Yamamoto T, Yamamoto N, Kageyama T, Sakai H, Fuse Y, Tsuihiji K, Tsukuura R. Definition of perforator flap: what does a "perforator" perforate? *Glob Health Med*. 2019 Dec 31;1(2):114-116. doi: 10.35772/ghm.2019.01009. PMID: 33330765; PMCID: PMC7731185.
4. Angrigiani C, Grilli D, Siebert J. Latissimus dorsi musculocutaneous flap without muscle. *Plast Reconstr Surg*. 1995 Dec;96(7):1608-14. doi: 10.1097/00006534-199512000-00014. PMID: 7480280.
5. Heitmann C, Guerra A, Metzinger SW, Levin LS, Allen RJ. The thoracodorsal artery perforator flap: anatomic basis and clinical application. *Ann Plast Surg*. 2003 Jul;51(1):23-9. doi:10.1097/01.SAP.0000054189.14799.F3. PMID: 12838121.
6. Stekelenburg CM, Sonneveld PM, Bouman MB, van der Wal MB, Knol DL, de Vet HC, van Zuijlen PP. The hand held Doppler device for the detection of perforators in reconstructive surgery: what you hear is not always what you get. *Burns*. 2014 Dec;40(8):1702-6. doi: 10.1016/j.burns.2014.04.018. Epub 2014 Jun 19. PMID: 24953858.
7. Chim H, Nichols DS, Chopan M. Ultrasound for Perforator Mapping and Flap Design in the Hand and Upper Extremity. *J Hand Surg Am*. 2023 Jun; 48(6): 595-601. doi: 10.1016/j.jhsa.2022.12.003. Epub 2023 Feb 3. PMID: 36740538.
8. Thomsen JB, Rindom MB, Rancati A, Angrigiani C. Thoracodorsal artery flaps for breast reconstruction-the variants and its approach. *Arch Plast Surg*. 2021 Jan;48(1):15-25. doi: 10.5999/aps.2020.01410. Epub 2021 Jan 15. PMID: 33503740; PMCID: PMC7861974.
9. Tenekeci G. Perforator Flaps: Principles and Techniques [Internet]. *Issues in Flap Surgery*. InTech; 2018
10. Khajuria A, Koshima I, Kannan RY. The Role of Supermicrosurgery and Arborization Capture in Improving Free-styled Propeller Flap Survival. *Plast Reconstr Surg Glob Open*. 2021 Dec 10;9(12):e3974. doi: 10.1097/GOX.0000000000003974. PMID: 34909356; PMCID: PMC8663866.
11. Yu XX, Yang SF, Ji CS, Qiu SQ, Qi YD, Wang XM. A novel computed tomography angiography technique: guided preoperative localization and design of antero-lateral thigh perforator flap. *Insights Imaging*. 2022 Dec 13;13(1):190. doi: 10.1186/s13244-022-01318-0. PMID: 36512153; PMCID: PMC9748003.

12. Rozen WM, Ashton MW, Pan WR, Kiil BJ, McClure VK, Grinsell D, Stella DL, Corlett RJ. Anatomical variations in the harvest of anterolateral thigh flap perforators: a cadaveric and clinical study. *Microsurgery*. 2009;29(1):16-23. doi: 10.1002/micr.20550. PMID: 18942652.
13. Sever C, Uygur F, Kulahci Y, Karagoz H, Sahin C. Thoracodorsal artery perforator fasciocutaneous flap: A versatile alternative for coverage of various soft tissue defects. *Indian J Plast Surg*. 2012 Sep;45(3):478-84. doi: 10.4103/0970-0358.105956. PMID: 23450715; PMCID: PMC3580346.
14. Li SQ, Zheng ZF, Li H, Zhang JF, Zheng Y, Lin LS. Clinical Study on the Thoracodorsal Artery Perforator Flap in Breast-Conserving Reconstruction of T2 Breast Cancer. *Surg Innov*. 2024 Feb;31(1):16-25. doi: 10.1177/15533506231212785. Epub 2023 Oct 29. PMID: 37899450.
15. Reddy T, Dikshit V, Tilak B, Ganesh M. Thoracodorsal artery perforator flap in immediate breast reconstruction: a series of twenty cases. *Int Surg J*. 2020; 7(1): 205-9.
16. Nizamoglu M, Hardwick S, Coulson S, Malata C. The use of the thoracodorsal artery perforator flap in both autologous and implant based breast reconstruction salvage surgery. *Clin Surg* 2020; 5: 3006.
17. Sui X, Qing L, Yu F, Wu P, Tang J. The versatile thoracodorsal artery perforator flap for extremity reconstruction: from simple to five types of advanced applications and clinical outcomes. *J Orthop Surg Res*. 2023 Dec 18; 18(1):973. doi: 10.1186/s13018-023-04480-3. PMID: 38110957; PMCID: PMC10726498.
18. Thomsen JB, Børsen-Rindom M, Rancati A, Angrigiani C. The propeller thoracodorsal artery perforator flap — designs for breast reconstruction and perspectives. *Ann Breast Surg* 2022; 6: 22.
19. Taglialatela Scafati S, Cavaliere A, D'Andrea F, Schonauer F. Thoracodorsal Artery Perforator Flap Anterograde Dissection: From Source Vessel to Perforator. *Plast Reconstr Surg Glob Open*. 2021 Feb 15;9(2):e3390. doi: 10.1097/GOX.0000000000003390. PMID: 33680647; PMCID: PMC7929618.
20. Le HQ, Hoang AD. Thoracodorsal Artery Perforator Flap for Chronic Radiation-Induced Ulcer of the Axilla in Vietnam. *Case Rep Oncol Med*. 2021 Oct 6;2021: 8478006. doi: 10.1155/2021/8478006. PMID: 34659849; PMCID: PMC8514962.
21. La Padula S, Pensato R, Pizza C, D'Andrea F, Roccaro G, Meningaud JP, Hersant B. The Thoracodorsal Artery Perforator Flap for the Treatment of Hidradenitis Suppurativa of the Axilla: A Prospective Comparative Study. *Plast Reconstr Surg*. 2023 Nov 1;152(5):1105-1116. doi: 10.1097/PRS.0000000000010435. Epub 2023 Mar 22. PMID: 36946904.

## Research Article

# Reconstructive Modalities in the Management of Rhino-Orbito Maxillary Mucormycosis

Fatima Askari,<sup>1</sup> Saad ur Rehman,<sup>2</sup> Shayan Shahid Ansari,<sup>3</sup> Rehan Abbas,<sup>4</sup> Maira Shoaib<sup>5</sup>

<sup>1-5</sup>Plastic Surgery Department, Shifa International Hospital, Islamabad, Pakistan

### Abstract

**Background:** Mucormycosis is considered as a medical emergency due to its rapid fatal nature. After aggressive surgical excision of facial mucormycosis, extensive defects with facial disfigurement are left behind which remain challenging for reconstructive surgeons.

**Objective:** Our study aimed to demonstrate different surgical modalities for reconstruction of rhino-orbito-maxillary mucormycosis.

**Methodology:** This retrospective study was carried out in Plastic Surgery Department of Shifa International Hospital from 1st January 2018 till 31st December 2023. A total of 14 patients were reported with mucormycosis of the head and neck region. Diagnosis was based on fungal potassium hydroxide and histopathology. Computed tomography or magnetic resonance imaging was performed to evaluate the extent of infection. After getting disease clearance by radical debridement and concomitant use of I/V amphotericin B, resultant defects were reconstructed by either padicle flap or free flap.

**Results:** There were 42.8% females and 57.1 % males with mean age of 47.7 years. The predisposing factors were diabetes in 8 (57.1%) patients, 3 (21.4%) patients were post-covid, 1 (7.1%) was post renal transplant, 1 (7.1%) was post-acute lymphocytic leukemia, whereas 1 (7.1%) had post RTA defect with no known co-morbid. Reconstruction was done by regional flaps in 14.2% and free flaps in 35.7% cases. The mean follow-up period was 17.8 months, with no recurrence of disease or flap failure.

**Conclusion:** Mucormycosis is a lethal disease, and its diagnosis requires high index of suspicion. Proper disease eradication is necessary for reconstruction with different autologous flaps to achieve good functional and aesthetic results.

**Received** | 01-08-2024 **Revision** | 12-08-2024 **Accepted** | 16-08-2024

**Corresponding Author** | Dr Fatima Askari, Shifa international hospital, Islamabad, Pakistan

**Email:** fatima.askari89@gmail.com.

**Keywords** | Mucormycosis, Reconstruction, free flaps, maxillary defects, potassium hydroxide (KOH).

### Introduction

Mucormycosis is considered to be the 3<sup>rd</sup> commonest opportunistic fungal infection after candidiasis and aspergillosis.<sup>1</sup> Facial mucormycosis is a rare entity that causes a rapidly advancing, destructive and perilous infection.<sup>2</sup> It gains entry through the respiratory tract via nose and spreads into the nasal cavity and paranasal sinuses from where it enters the orbit through direct or hematogenous route with possible further progression into intracranial region as rhino-orbital-cerebral mucor-

mycosis which is the most common type of mucormycosis.<sup>2,3</sup> It mostly attacks immunocompromised hosts with poorly controlled diabetes mellitus or diabetic ketoacidosis, immunosuppressive therapy from chronic steroids, history of organ transplant, hematologic malignancies and hemochromatosis.<sup>3</sup>

Invasive Mucormycosis is categorized as rhino-orbital-cerebral, pulmonary, cutaneous, gastrointestinal, disseminated, and miscellaneous.<sup>4,8</sup> Mucormycosis was recognized as a lethal and untreatable disease until the

advent of amphotericin as a cure in 1960.<sup>5</sup> Recognition of disease requires high index of suspicion. Prompt diagnosis should be made on fungal KOH and histopathology.<sup>6</sup>

Management of mucormycosis is complex and challenging. This study highlights the effectiveness of multidisciplinary approach for complete eradication and reconstruction of defect. With recent medical and surgical advances, it has become possible to (i) treat the underlying comorbidity (ii) early commencement

of antifungal therapy, (iii) aggressive surgical resection of the affected tissues, (iv) reliable reconstruction and proper rehabilitation.<sup>7</sup>

### Methodology:

This retrospective study was approved by institutional review board and conducted in department of plastic surgery, Shifa International Hospital, Islamabad over a period of 6 years from 1<sup>st</sup> January 2018 till 31<sup>st</sup> December 2023. All patients who underwent treatment for mucor-

**Table 1:** Summary of demographic and clinical characteristics and management of patients

S. No	Age / Sex	Predisposing Factors	Debridements (No)	Surgical Resection	Flap Type	Complication	Follow Up (M)	Secondary Procedures
1	40/F	Diabetic	10	right maxilla, nasal side wall, palate	temporalis flap, cheek rotation flap and forehead flap	Nil	36	Scar revision, fat grafting, alar readjustment
2	45/M	Diabetic	4	left orbital exenteration with left total maxillectomy + palatal defect	ALTF	Nil	16	Flap debulking
3	64/M	Diabetic	6	B/L subtotal maxillectomy with >50% palatal defect	ALTF	Nil	13	Nil
4	39/M	RTA (trauma)	4	cutaneous mucormycosis of left side of face + forehead sparing left eye	ALTF + Skin graft for forehead	Nil	24	Flap debulking, FTSG for lower eyelid
5	9/F	post ALL (Acute lymphocytic leukemia)	5	left nasal defect, maxilla and left orbital exenteration	Myocutaneous latissimus dorsi flap	Nil	30	Flap debulking, Nasal augmentation with rib graft, socket creation
6	52/F	post renal transplant	4	B/L maxillary, upper alveolar process, palatal defect	Osteocutaneous fibula flap	Nil	16	Nil
7	51/M	post covid	7	left orbital exenteration with left total maxillectomy+ palatal defect	ALTF	palatal fistula	25	fistula repair
8	47/F	post covid	4	Left subtotal maxillectomy + >50% palate	ALTF	Nil	14	Nil
9	52/F	post covid	4	Left hemi palatal defect	temporalis flap	Nil	13	Nil
10	49/F	Diabetic	5	Right orbital exenteration	free radial artery forearm flap	Nil	12	Scar revision
11	50/M	Diabetic	7	B/L maxillary, upper alveolar process, palatal defect	osteocutaneous fibula flap	Nil	18	Nil
12	54/M	Diabetic	5	Right hemifacial skin resection + subtotal maxillectomy	free radial artery forearm flap	Nil	21	Scar revision
13	57/M	Diabetic	6	left subtotal maxillectomy orbital exenteration	free radial artery forearm flap	Nil	10	Nil
14	55/M	Diabetic	5	left orbital exenteration with left maxillectomy+ palatal defect	ALTF	Nil	9	Flap debulking

**Abbreviations:** ALTF=anterolateral thigh flap, B/L= bilateral, RTA=road traffic accident, FTSG=full thickness skin grafting

mycosis of the head and neck region were included in the study. Patient's demographics such as age, sex, predisposing factor, area of defect, flap type, complications, follow-up, and recurrence were noted.

Inclusion criteria was patients having facial mucormycosis involving disease in maxillary and naso-orbital areas who had undergone surgical excision and reconstruction with flaps. Exclusion criteria was patients having intracranial extension and mucormycosis involving other than head and neck region such as limbs or trunk. A multidisciplinary approach was established, and patients were evaluated by head and neck surgeon, plastic surgeon, medical specialist, infectious disease, histopathologist, radiologist. Prompt diagnosis was made, based on fungal KOH and histopathology. Computed tomography or magnetic resonance imaging was performed to evaluate the extent of disease. All patients were treated initially by head and neck surgeon and multiple sessions of surgical debridement were done until clearance was achieved. Meanwhile injectable amphotericin B was given to patients for 3-4 weeks that was later switched to oral Posaconazole 300 mg BD on day 1 followed by 300 mg OD for the next 45 days. Follow-up protocol included monitoring of erythrocyte sedimentation rate (ESR) and C-reactive protein (CRP) along with renal function tests.

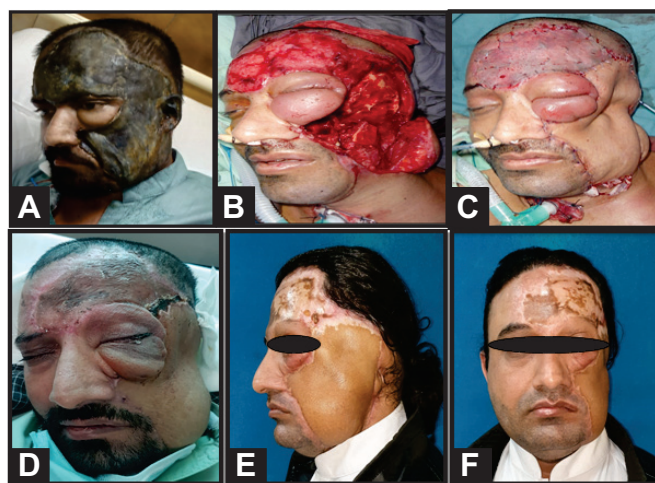After complete resolution of infection, when the patients were considered disease free by head and neck surgeon, they were referred to plastic surgery. Defect sizes were assessed and reconstruction with autologous tissue was done in the form of local, regional, or free flaps. Timing of reconstruction was considered immediate if done after first debridement, Early if done within 2 weeks of serial debridement and delayed if done after 4 weeks. Patients were assessed for complications and recurrence in their follow-ups postoperatively for 1 year.

## Results:

A total of 14 patients in our institution were diagnosed with facial mucormycosis out of which 13 (92.8%) were rhino-orbito-maxillary whereas as 1 (7.1%) was diagnosed with cutaneous mucormycosis. There were 42.8% females (6/14) and 57.1 % males (8/14). Mean age was 47.7 ranging from 9 -68 years. The predisposing factors were diabetes in 8 (57.1%) patients, 3 (21.4%) patients were post-covid, 1 (7.1%) had road traffic accident with no known co-morbid, 1 (7.1%) was post renal transplant and 1(7.1%) was post-acute lymphocytic

leukemia chemotherapy. Twelve (85.7%) cases were diagnosed and treated primarily in our hospital whereas 2 (14.2%) cases with established diagnosis of mucormycosis came to us for further treatment. One case of cutaneous mucormycosis was treated in outside facility for coverage with pectoralis major flap and presented to us with recurrence for revision. In each individual case after completion of the medical management with I/V amphotericin B for 3-4 weeks and a mean of 5.4 surgical debridements, we established a disease-free status with repeat biopsy and fungal KOH from the previously infected areas. After thorough debridement we came across defects of variable sizes and depth. Their respective surgical resections are mentioned in (Table 1).

For these variety of defects different surgical modalities were used. Reconstruction was planned according to the defect (Figure1-3). Delayed reconstruction was done in all cases. Two (14.2%) patients were reconstructed with regional flaps including temporalis muscle flap, cheek rotation flap and forehead flap whereas in 12 (85.7%) cases reconstruction was done with free flaps. In our study, Anterolateral thigh flap was used 6 (42.8%) patients, osteocutaneous free fibula in 2 (14.2%) patients, radial forearm free flap in 3 (21.4%) patients and myo-cutaneous LD flap in 1 (7.1%) patient.

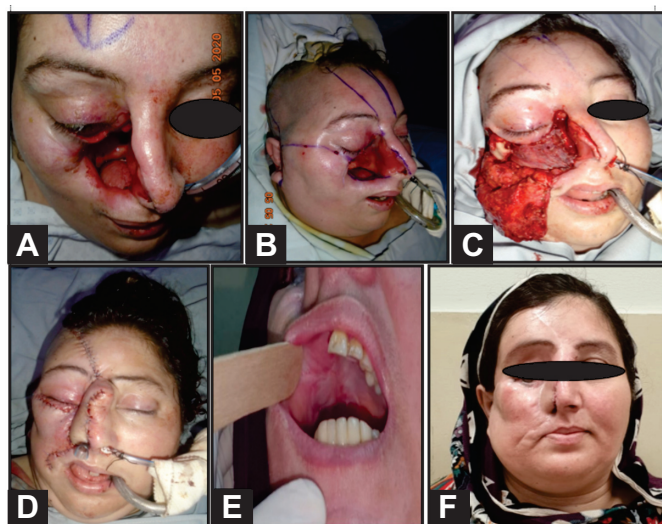

**Figure1:** *A) case of cutaneous mucormycosis in which skin changes occurred 5 days after RTA. B) intraoperative picture showing debrided part of previously done pectoralis major flap and final defect. C) coverage done with Anterolateral thigh flap and split thickness skin graft for forehead. D) early follow-up at 1 month. E,F) follow-up at 1 year after flap debulking and lower lid full thickness skin grafting.*

Secondary procedures were done in 8(57.1%) patients for aesthetic improvement which included flap debul-

king, scar revision, fat grafting, alar readjustment, nasal augmentation. Among the patients included in our study, there was no mortality and survival rate of all flaps was 100% with no free flap failure. All patients were closely followed after discharge and none of the cases had a recurrence.

Only 1 (7.1%) patient had a complication of palatal fistula identified at 5th month for which fistula repair was done. The mean follow-up was 17.8 ranging from 9 to 36 months.



**Figure 2:** *A) Young lady with large defect of right cheek, nasal dorsum, and palate with visible tongue at base. B) Markings for forehead flap, temporalis muscle flap and cheek rotation advancement flaps. C) Temporalis muscle flap inset done to reconstruct palate and fill the dead space. D) Per-operative pic showing inset of forehead and cheek flaps. E) Intra-oral view showing good mucosalization of temporalis muscle. F) Frontal view of follow up at 6 months.*

## Discussion:

Mucormycosis is an angio-invasive fungal infection that forms intraluminal thrombosis that eventually leads to tissue necrosis by restricting delivery and penetration of drugs into infected hypovascularized tissues.<sup>10</sup> Rhino-orbital-cerebral mucormycosis is the most common presentation of disease after which cutaneous form is the next in line.<sup>8,10</sup> The mean age of our patients is comparable to studies of Rao et al<sup>16</sup> and Ojha et al.<sup>18</sup> The most frequent initial manifestation of mucormycosis is sinusitis, orbital cellulitis, eye or facial pain/ swelling and facial numbness<sup>9</sup> which was also seen in our patients. Due to vascular thrombosis and tissue necrosis black dusky eschars are formed on the nasal mucosa or palate that are pathognomonic of mucormycosis. This ulceration

of the hard palate stipulates disease progression beyond maxillary sinuses<sup>17,19</sup>.

Urgent diagnosis with KOH smear or tissue biopsy is mandatory.<sup>11</sup> Biopsy is considered as gold standard in terms of recognition of wide, aseptate, ribbon like hyphal structures branching at right angles<sup>12</sup>. It is considered unreasonable to wait for fungal cultures in light of clear clinical signs and symptoms of mucor and one should not delay beginning of antifungal treatment to inhibit from further progression of disease.<sup>3</sup> Amphotericin B was reported to be drug of choice.<sup>10,12</sup> Nephrotoxicity was the most serious side effect of this drug due to which in 1991 a less toxic and more potent form, liposomal amphotericin was developed and used in patients with worsening renal functions<sup>12</sup>. In our study liposomal amphotericin was not used due to its high expense, so conventional amphotericin B has been the mainstay of antifungal treatment with satisfactory results that was later switched to oral Posaconazole with an initial dose of 300mg twice a day for 1 day followed by 300mg daily for 6 weeks.<sup>14</sup>

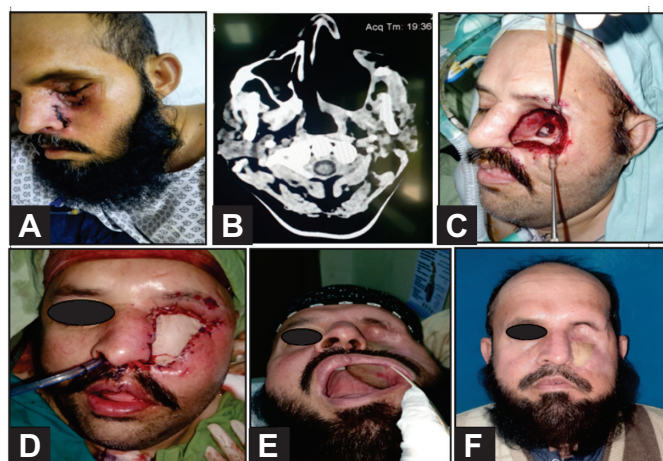It is crucial to radically excise mucor inflicted tissues (as in malignancy) so that no residual infected area is left behind, therefore huge complex defects are created with significant functional impairment and aesthetic disfigurement that are challenging to reconstruct.<sup>13</sup> To achieve disease free margins in our study, all infected tissues were excised with 1 cm margin beyond the point of affected area with removal of involved part of bone which is similar to other studies.<sup>14,15</sup>

After confirmation of disease elimination, reconstruction is planned with the consultation of head and neck surgeon. According to the assessment of area, size and volume of defect the plastic surgeon decides whether to reconstruct using a prosthesis or autologous tissue.<sup>7</sup>

We believe that autologous reconstruction is superior as it brings vascularized tissue in an area of infection and combats residual infection by good blood supply, it avoids wear and tear by covering the exposed structures with the downside of being time consuming procedure that needs expertise and may require secondary procedures for better cosmesis.<sup>7</sup>

Anitha et al in their study used pedicled flaps after resection for primary coverage and found some complications of flap necrosis. We believe local and pedicled flaps encounter difficulty in reaching mid facial defects. Therefore, they do not provide enough tissue and adequate bulk to fill composite facial defects, in our study pedicled flaps were used in only 2 of our patients at the

time of covid wave to shorten the operative time due to hospital policy.



**Figure3:** A) *Mucor* extension into left orbit, maxilla and palate, serial excisions showing left enucleation. B) left side defect shown in CT scan. C) final defect at the time of reconstructive surgery. D) reconstruction done with Anterolateral thigh flap. E, F) follow-up pictures at 8 months.

Gupta,<sup>10</sup> Humnekar,<sup>13</sup> Rao<sup>16</sup> and Allensworth strongly suggests usage of free flaps in their studies to attain superior results in reconstruction of complex 3-D defects as compared to pedicled flaps. Free flaps have a reliable blood supply and superior coverage of complex mid facial defects. In our study we have used variety of free flaps in accordance with different composite defects showing satisfactory results.

There is also a debate on immediate reconstruction or whether to delay it. In a literature review, most of the studies 13/16 had done delayed reconstruction with an average time of 16.7 weeks (range 2-36 weeks) and immediate reconstruction was reported by two authors 3/16 only.<sup>15</sup> Our study also states delayed reconstruction once the disease is cured. Other authors have also reported multiple debridement to establish disease free status and undergone delayed reconstruction<sup>12,13,17</sup> which is not in favor of immediate reconstruction done by Gupta et al<sup>10</sup> and Ojha et al.<sup>18</sup>

In the present study there was no flap failure or recurrence of mucormycosis which is similar to studies presented by Ojha et al<sup>18</sup> and Gupta et al.<sup>10</sup>

The various complications reported in literature review by Palacios et al are oronasal fistula, naso-orbital fistula and oropharyngeal fistula, recurrent bleed, exposed meninges, CSF leak etc.<sup>[15]</sup>. In our series only 1 patient developed oronasal fistula and after fistula repair satis-

fying results were achieved. Our study has a mean follow up of 17.8 months compared to Parvati et al.<sup>11</sup> Flap survived in all patients with good wound healing and acceptable esthetic and functional results.

## Conclusion

Mucormycosis is a fatal disease if not treated early, its diagnosis requires high index of suspicion. Reconstruction should be delayed until complete eradication of disease is achieved. Pedicled flaps are used to cover small, isolated defects of orbit or palate but they are found to be inadequate for extensive defects. Free flaps give freedom of design and ability to do 3-D reconstruction and found to be a reliable option for complex maxillofacial defects.

**Source of Funding:** None.

**Conflict of interest:** None.

**Author's contribution:**

**Dr. Fatima Askari:** Conception and design of the study, data collection, Drafting the work, analysis and interpretation, Final approval of the version to be published and accountable for all aspects of the work in ensuring that questions related to the accuracy or integrity of any part of the work are appropriately investigated and resolved.

**Dr. Saad ur Rehman:** Conception and design of the study, critical revision of the article and final approval of the article to be published

**Dr. Shayan Shahid Ansari:** Article Editing, Manuscript Revision analysis & interpretation of data

**Dr. Rehan Abbas:** Data collection, Article Editing, Manuscript Revision, analysis and interpretation of data

**Dr. Maira Shoaib:** Study design, drafting of work, Data Collection and analysis and interpretation

## References

1. Rathee M, Singh S, Malik S, SD AM. Reconstruction and rehabilitation of maxillary defects secondary to mucormycosis. *Saudi J Oral Dent Res.* 2022;7(1):1-7.
2. Gupta S, Goyal R, Kaore NM. Rhino-Orbital-Cerebral Mucormycosis: Battle with the Deadly Enemy. *Indian J Otolaryngol Head Neck Surg.* 2020 Mar;72(1):104-111. doi: 10.1007/s12070-019-01774-z. Epub 2019 Dec 5. PMID: 32158665; PMCID: PMC7040141.
3. Maini A, Tomar G, Khanna D, Kini Y, Mehta H, Bhagyasree V. Sino-orbital mucormycosis in a COVID-19 patient: A case report. *Int J Surg Case Rep.* 2021 May; 82:105957. doi: 10.1016/j.ijscr.2021.105957. Epub 2021 May 4. PMID: 33964720; PMCID: PMC8093005.

4. Barman Roy D, Gupta V, Biswas A, Verma M. Early Surgical Intervention Followed by Antifungals in Rhino-Orbital Mucormycosis in Patients With COVID-19 Favors Clinical Outcome: A Case Series. *Cureus*. 2021 Aug 14;13(8):e17178. doi: 10.7759/cureus.17178. PMID: 34548980; PMCID: PMC8437210.
5. Murthy R, Gote YS, Bagchi A. Localized surgical debridement for the management of orbital mucormycosis. *Indian J Ophthalmol*. 2022 Feb;70(2):649-652. doi: 10.4103/ijo.IJO\_1635\_21. PMID: 35086255; PMCID: PMC9023913.
6. Pai V, Sansi R, Kharche R, Bandili SC, Pai B. Rhino-orbital-cerebral Mucormycosis: Pictorial Review. *Insights Imaging*. 2021 Nov 12;12(1):167. doi: 10.1186/s13244-021-01109-z. PMID: 34767092; PMCID: PMC 8587 501.
7. Srikanth V, Pradeep KN, Anantheswar YN, Ashok BC, Sudarsahn R, Bhath R. Cranio-facial mucormycosis—the plastic surgeon's perspective. *Eur J Plast Surg*. 2020; 43:239-46.
8. Li CX, Gong ZC, Pataer P, Shao B, Fang C. A retrospective analysis for the management of oromaxillofacial invasive mucormycosis and systematic literature review. *BMC Oral Health*. 2023 Feb 21;23(1):115. doi: 10.1186/s12903-023-02823-4. PMID: 36810012; PMCID: PMC 9942087.
9. Rapidis AD. Orbitomaxillary mucormycosis (zygomycosis) and the surgical approach to treatment: perspectives from a maxillofacial surgeon. *Clin Microbiol Infect*. 2009 Oct;15 Suppl 5:98-102. doi: 10.1111/j.1469-0691.2009.02989.x. PMID: 19754767.
10. Gupta S, Goil P, Mohammad A, Escandón JM. Mucormycosis Management in COVID-19 Era: Is Immediate Surgical Debridement and Reconstruction the Answer? *Arch Plast Surg*. 2022 May 27;49(3):397-404. doi: 10.1055/s-0042-1748654. PMID: 35832156; PMCID: PMC9142224.
11. Parvati R, Subbalaxmi MV, Srikanth R, Sajani P, Koteswara Rao RV. Is Single-stage Microvascular Reconstruction for Facial Mucormycosis Safe? *Indian J Plast Surg*. 2021 Apr;54(2):130-137. doi: 10.1055/s-0041-1731961. Epub 2021 Jul 5. PMID: 34239233; PMCID: PMC8257306.
12. Cheruvu VPR, Khan MM. Reconstruction in Rhino-Orbital-Cerebral Mucormycosis Survivors: A Systematic Review. *Eplasty*. 2022 Jun 14;22:e20. PMID: 35873068; PMCID: PMC9275414.
13. Kala PC, Dixit PK, Katrolia D, Karmakar S, Humnekar A, Singla P, Singh AP. Post-COVID-19 Rhino-Orbital-Maxillary Mucormycosis Defect: Our Surgical Experience with Single Stage Delayed Reconstruction Using Free Flap. *Indian J Plast Surg*. 2024 Apr 23; 57(5): 379-386. doi: 10.1055/s-0044-1785489. PMID: 39552810; PMCID: PMC11567769.
14. Singh VK, Haq A, Sharma S, Kumari A. Early Reconstruction with Locoregional-Free Flaps in Post-COVID-19 Rhino-orbital-cerebral Mucormycosis Craniofacial Deformities: A Single-Center Clinical Experience from India. *Surg J (N Y)*. 2024 Jan 15;10(1):e1-e10. doi: 10.1055/s-0043-1778652. PMID: 38528856; PMCID: PMC10789507.
15. Palacios JJ, Hanson EV, Rendon MA, Infante RS. J reconst *Microsurg Open*. 2019 Jul;4(02):e65-72.
16. Rao N, Agrawal A, Kapoor A, Mago V, Vathulya M, Chattopadhyay D. Restoring Quality of Life: Assessing the Impact of Free Flap Reconstruction in Coronavirus Disease 2019-Associated Rhino-Orbital Mucormycosis Patients. *Indian J Plast Surg*. 2023 Oct 16;56(6):507-513. doi: 10.1055/s-0043-1776011. PMID: 38105868; PMCID: PMC10721371.
17. Saad RH, Mobarak FA. The diversity and outcome of post-covid mucormycosis: A case report. *Int J Surg Case Rep*. 2021 Nov;88:106522. doi: 10.1016/j.ijscr.2021.106522. Epub 2021 Oct 18. PMID: 34692373; PMCID: PMC8522488.
18. Ojha T, Jain M, Gupta P. Single-Stage Reconstruction of Maxillectomy and Midfacial Defects in Cases of Covid Associated Mucormycosis. *Indian J Otolaryngol Head Neck Surg*. 2022 Oct;74(Suppl 2):3327-3332. doi: 10.1007/s12070-022-03121-1. Epub 2022 Sep 9. PMID: 36105434; PMCID: PMC9462606.

## Research Article

# Comparison of Muscle Sparing Latissimus Dorsi Flap Vs Split Thickness Skin Graft for Post Burn Inframammary Fold Contracture Release in Terms of Contracture Recurrence and Breast Contour

Maria Ashraf,<sup>1</sup> Ammara Rabbani,<sup>2</sup> Mehwish Ihsan,<sup>3</sup> Kamran Khalid,<sup>4</sup> Yawar Sajjad,<sup>5</sup> Zain ul Abidin<sup>6</sup>

<sup>1,3-6</sup> Jinnah Burn and Reconstructive Surgery Center, Lahore; <sup>2</sup> Khwaja Muhammad Safdar Medical College, Sialkot

### Abstract

**Background:** Childhood thermal injuries of anterior chest wall lead to developmental breast abnormalities. Conventional IMF release methods include release of restrictive scars and addition of thick split thickness skin grafts (STSG). However, it may lead to recurrence, poor skin texture and projection deformity. The pedicled muscle sparing latissimus dorsi (MSLD) flap overcomes these complications.

**Objective:** The aim of this study is to compare the outcomes between these two procedures in terms of contracture recurrence and breast aesthetics and donor site morbidity.

**Methodology:** It was a randomized control trail conducted for a period of one year from April, 2023 to April, 2024 at Jinnah burn & reconstructive surgery Centre, Lahore. Post-pubertal females with small to medium sized breast having post-burn IMF contracture and lower pole projection deformity were included. Lower pole breast reconstruction was done either with MSLD flap or STSG. Patients were randomly allocated to one of the two groups. Three months postoperatively, patients were assessed for breast aesthetics using modified breast aesthetic scale, latissimus dorsi function, Vancouver scar scale and contracture recurrence.

**Results:** Out of Eighteen patients, thirteen were reconstructed with horizontal skin paddle MSLD flap and rest with STSG. Scar characteristic, breast aesthetic score and over all satisfaction were better for MSLD then STSG group ( $P < 0.05$ ). Contracture recurrence was noted only in two patients and both were reconstructed with thick split thickness skin graft.

**Conclusion:** For IMF contracture release, the Pedicled MSLD flap offers an indispensable tool to the arsenal of reconstructive surgeon in post-burn breast reconstruction. It offers superior aesthetic results and minimal recurrence as compared to STSG without increased morbidity.

**Received** | 23-09-2024 **Revision** | 06-12-2024 **Accepted** | 19-12-2024

**Corresponding Author** | Dr. Maria Ashraf, Jinnah burn and reconstructive surgery center Lahore .

**Email:** dr.mariaashraf@yahoo.com

**Keywords** | Post-burn breast deformity , Inframammary fold contracture, muscle sparing latissimus dorsi flap, split thickness skin graft.

### Introduction

Childhood thermal injuries affecting the anterior chest wall often lead to notable deformities in breast contour during puberty. This impedes normal breast development, primarily due to extensive scarring and contractures, resulting in a projection deformity rather than parenchymal damage to the breast.<sup>1</sup> Nonetheless, breast mound deficiency, disfigurement and asymmetry sig-

nificantly impact the emotional well-being of the patient.<sup>2</sup>

Particularly, inframammary fold (IMF) definition and the lower pole area of the breast plays a pivotal role in breast contour formation.<sup>3</sup> Post-burn scarring in this region often leads to projecting deformity and the downward displacement of the NAC due to Inframammary Fold (IMF) contracture.

Conventional methods for correcting IMF deformities typically involve releasing restrictive scars and reconstructing with thick split-thickness or full thickness skin grafts.<sup>4</sup> However limitations of skin graft in inframammary sulcus include inadequate improvement in projection deformity, altered skin texture, poor graft take and contracture recurrence.<sup>5</sup>

Alternative viable options encompass Z-plasty, local/regional flaps, pre-expanded flaps, fat grafting, free flaps and reconstruction with breast prostheses in severe deformity.<sup>6</sup> An ideal reconstruction technique should comprehensively address breast mound deficiency, NAC deformity, breast contour and volume concerns<sup>7</sup>.

The Pedicle muscle sparing latissimus Doris flap (MSLD), already described in literature for breast reconstruction, best archives these objectives.<sup>8</sup>

The primary objective of this study is to compare outcomes of post-burn IMF contracture release and lower pole breast reconstruction utilizing a muscle-sparing latissimus dorsi flap versus split-thickness skin grafts in terms of contracture recurrence and breast aesthetics.

## Methodology

From April 2023 to April 2024, a randomized control trial at breast clinic of Jinnah burn and reconstructive surgery center, Lahore enrolled eighteen females presenting with small to medium-sized breasts, lower pole projection deformity, and inferior mammary fold (IMF) contracture. Patients were assigned randomly in 1:1, using block randomization to ensure equal size groups, to have lower pole breast reconstruction with muscle sparing latissimus dorsi flap or split thickness skin graft. All the deformities stemmed from prepubertal burns, including scald, flame, or chemical burns.

Patients with burns on their back, with history of pre-

vious flap harvest and patients having large sized breasts were excluded. Detailed procedural information was documented, and informed consent was obtained.

Preoperative assessment included a comprehensive medical history, thorough physical examination including location and type of deformity and its anatomical extent, and baseline laboratory investigations. Preoperative, Intra-operative and post-operative photographs were taken in all the patients.

The average follow-up period was three months. Patient satisfaction with breast aesthetics was evaluated using modified validated breast aesthetic scale,<sup>9</sup> as mentioned in Table-1.

Post-operative photographs were evaluated by a panel of two plastic surgeons and one plastic surgery resident, for breast aesthetic score. Contracture recurrence was assessed subjectively by surgeon other than the operating surgeon.

Donor site scar was assessed by using Vancouver scar scale (VSS)<sup>10,11</sup> Assessment of latissimus dorsi (LD) function included medical research council (MRC) muscle power scale and comparison of shoulder movements and muscle power with the non-operated side. Additionally post-operative seroma formation and hospital stay duration was also noted.

Quantifiable variables were compared between two groups using student's t-test. Data were analyzed using SPSS-21 software. A p-value <0.05 was considered statistically significant with 95% confidence interval.

## Surgical Techniques

Preoperative markings were meticulously performed with the patient in a standing position, delineating the mid-sternal line, breast meridian, inframammary fold,

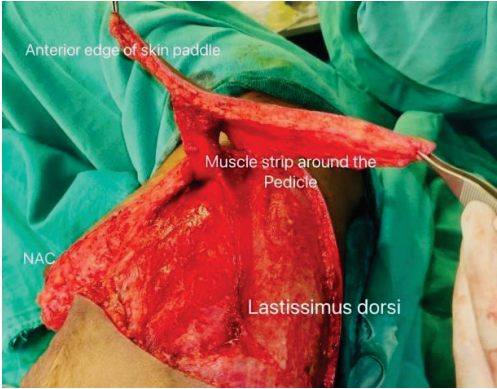
**Table 1:** Modified breast aesthetic scale

	1	2	3	4	5
<b>Breast symmetry</b>	severe asymmetry	Moderate asymmetry	Mild overall asymmetry	Mild asymmetry	Symmetric
<b>Volume</b>	Severe insufficiency	Moderate insufficiency	Mild overall insufficiency	Mild insufficiency	Proportionate volume
<b>Contour</b>	Severe contour deformity	Moderate contour deformity	Mild overall contour deformity	Mild contour deformity	Natural contour
<b>Inframammary fold</b>	Not identified	Poorly identified	Marked displacement	Mild displacement	Excellent position
<b>Scar</b>	Poor hypertrophic scar	Poor scar (wide,, colour mismatch, hyperpigmented)	Fair scar (depressed, wide, colour mismatch)	Good scar (thin, mild colour mismatch)	Excellent scar (thin, good colour match)
<b>Overall appearance</b>	Unacceptable	Poor	Good	Very good	Excellent

sternal notch to nipple distance (SN-N), and nipple to inframammary fold distance (N-IMF)<sup>12</sup> Additional markings were made in the upright position to identify scarred areas and IMF contractures to be addressed. The lateral edge of the latissimus dorsi and the tip of the scapula were also marked.

Skin paddles were designed transversely inline with the new IMF, with the anterior edge positioned 2cm medial to border of latissimus dorsi muscle, to capture perfusion from thoracodorsal artery descending branch perforators. Following incision at the site of new IMF markings and elevation of glandular tissue from the chest wall, dissection proceeded to release the breast from the 4<sup>th</sup> to 6<sup>th</sup> rib in pre-pectoral plane.<sup>13</sup> Bifurcation of thoracodorsal artery is usually located about 5.1cm from posterior axillary fold (range is 2.1-7.5cm) and 2.2 cm from lateral edge of lastissimus dorsi.<sup>14,15</sup>

Marked skin paddle incised and lateral border of lastissimus dorsi was identified and raised. On its deep surface, descending branch of thoracodorsal artery identified and dissected up to its origin, followed by vertical splitting of the latissimus dorsi muscle to harvest a 3-5cm strip of muscle around the Pedicle and leaving muscle bulk behind. This step is demonstrated in figure1. The flap was tunneled for transposition to breast lower pole. Chest wall defect was covered with the local tissue.



**Figure 1:** Intraoperative view of muscle sparing lastissimus dorsi flap harvest , based on descending branch of thoracodorsal artery , including only 3cm muscle strip around the Pedicle while preserving rest of muscle in place .

Results

A total of eighteen patients (equating to 26 breasts) were included in the study, with eight patients presenting bilateral IMF contractures and the remainder unilateral. Scald burns were the most common etiology (n=11), followed by flame burns (n=6) and one case of chemical

burn, all occurring during the prepubertal period. The mean age at the time of operation was 17.5 years.

All patients exhibited IMF contracture, flattened lower poles, and breast mound deficiency, with five patients also presenting with severe anterior trunk scarring.

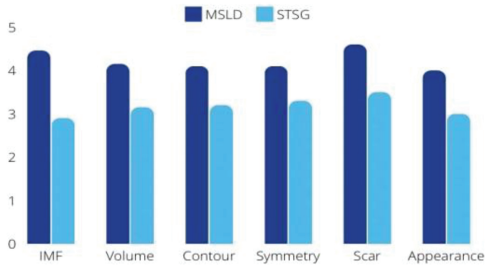
Reconstruction of the IMF was accomplished using the Pedicle muscle sparing latissimus dorsi (MSLD) flap in eight patients (13 breasts) and thick split-thickness skin grafts in the remaining ten patients (13 breasts). The average skin paddle sizes was ranging from 6-8cm in width and 14-24cm in length as mentioned in Demographic details are mentioned in table2.

Satisfactory breast contour outcomes were achieved in all patients reconstructed with MSLD, characterized

**Table 2:** Demographics

Characteristics	Number of patients (n)
Total number of patients	18
Unilateral cases	10
Bilateral cases	8
Reconstruction with MSLD	8 (13 breasts )
Reconstruction with STSG	10 (13 breasts)
<b>Etiology</b>	
Scald	11
Flame	6
Chemical	1
Mean age	17.5±2.3 Y
<b>Mean hospital stay</b>	
MSLD	8.3±2.9
STSG	3.7±0.8

by a convex lower breast pole, increased projection, and reshaped IMF. In contrast, patients treated with thick split-thickness skin grafts demonstrated lower satisfaction rates and a higher incidence of contracture recurrence. 3.7±0.8. These are depicted in figure2.

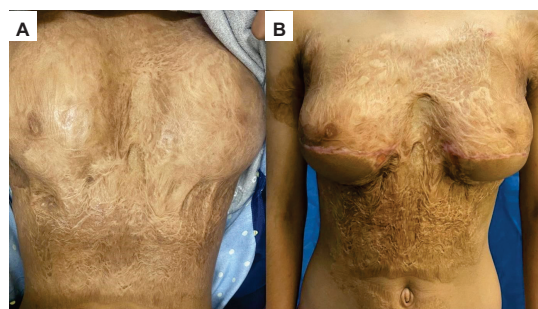


**Figure 2:** Mean score for evaluated Inframammary fold deformities, breast volume, contour, symmetry, breast scar and overall breast aesthetic appearance. The results were 4.4 vs 2.9 for Inframammary fold definition, 4.1 vs 3.9 for breast volume,4.1 vs 3.2 for contour, 4.1 vs 3.3 for breast symmetry, 4.6 vs 3.5 for breast scar and 4.0 vs 3.0 for overall breast aesthetic appearance.

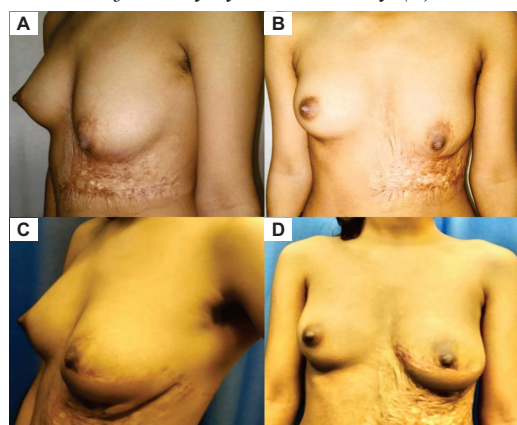
No seroma formation was observed at any MSLD flap donor site. Latissimus dorsi function was preserved in all patients, as evidenced by shoulder girdle active range of movement and muscle power.

Minor complications included distal tip necrosis, occurred in one patient (2 breasts) and wound dehiscence in one, both were managed conservatively. No instances of contracture recurrence were observed in any patient reconstructed with muscle sparing latissimus dorsi flap, however contracture recurrence was noted in two patients having 3<sup>rd</sup> and 4<sup>th</sup> degree flame burn with severe anterior trunk scarring, reconstructed with STSG.

The association between donor site, pigmentation and pliability at three months follow up for graft vs flap was significant ( $p < 0.05$ ). Compared with MSLD, patients reconstructed with STSG were less satisfied with donor site scar. (Table 3). However there was no significant difference between two patients group with respect to donor site scar vascularity and height representative patients of MSLD group are shown in figure 3 & 4 and representative patient of the group treated with STSG is shown in figure 5.

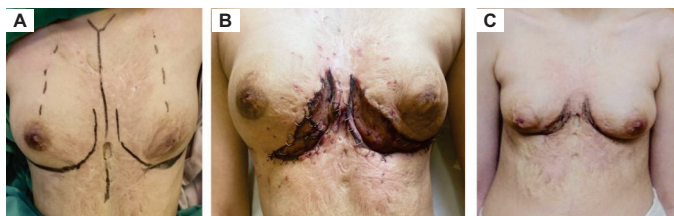

**Figure 3:** A 15-years old female presented with bilateral post-burn breast projection deformity with NAC distortion, IMF contracture and lower pole flattening. (a) Contracture release and breast reconstruction was done with bilateral MSLD flap. The follow up results at 3 months shows well defined IMF and rectification of projection deformity symmetrically (b).



**Figure 4:** A 17 years old female presented with post-

burn breast deformity having IMF contracture and breast mound deficiency on left side (a) pre-op oblique (b) pre op frontal view. IMF contracture release and breast reconstruction was done with MSLD flap. Follow up results shown at three months, with well defined IMF, convex lower pole and adequate projection. (c) post-op oblique and (d) post-op frontal.



**Figure 5:** A 24-years old female with post scald burn bilateral breast deformity. Reconstruction was done with split thickness skin graft bilaterally. Pre operative view (a), one week flap (b), 3 month flap (c)

**Table 3:** Mean score with different aspects of the Vancouver scar scale.

Scores	MSLD	STSG	p-value
Pigmentation	0.3 ± 0.7	1.53 ± 0.87	0.001
Pliability	0.38 ± 0.6	1.84 ± 1.62	0.008
Vascularity	0.07 ± 0.2	0.15 ± 0.3	0.55
Scar height	0.07 ± 0.27	0.8 ± 0.9	0.17

### Discussion:

Burn injuries, particularly in childhood, present a significant concern, ranking as the fifth most prevalent non-fatal injuries among children.<sup>16</sup> The trunk emerges as the third most affected body area, with breast involvement being a common occurrence.<sup>17</sup> Despite a global reduction in childhood burn mortality rates, there's been a notable uptick in patients seeking breast reconstruction to address post-burn deformities. Post burn deformities can either be linked to skin envelope or underlying glandular tissue. With varying degree of severity, it includes underdeveloped breast due to rigid scarring, inframammary fold contracture, altered skin texture, reduced projection, displaced or hypo-plastic nipple areola complex.<sup>18</sup> Unilateral deformity results in significant asymmetry. Post burn deformity can be associated with pain and significant social stigma, psychosocial effects of asymmetry in case of unilateral burn deformity and inability to lactate due to obliterated lactiferous ducts.<sup>19</sup>

Post-burn breast reconstruction encompasses a spectrum of reconstructive techniques, each tailored to address the unique challenges posed by the non-pliable, burnt tissue envelope. The reconstructive goals encompass

a multifaceted approach, including scar tissue release, restoration of breast volume, repositioning of the nipple-areolar complex (NAC), correction of breast mound deficiencies and rectification of projection deformities by releasing Inframammary fold (IMF) contracture. Reconstruction should be done at an age at which normal breast development would have been complete, may be years or decades after initial injury.<sup>20</sup>

Central to achieving optimal breast contour is the intricate three-dimensional topography, heavily influenced by the lower breast pole, which imparts its characteristic convex shape and slight ptosis. Inframammary fold contracture has predominant effect on lower pole development leading to projection deformity. Hence, meticulous attention to lower pole reconstruction and inframammary fold (IMF) release assumes paramount importance in ensuring favorable aesthetic outcomes. The primary technique historically employed for post-burn breast reconstruction involves inframammary scar tissue release coupled with thick split-thickness or full-thickness skin grafting, or grafting along with the artificial dermal matrix.<sup>21</sup> However, skin graft either thickness split thickness or full thickness, have inferior graft take on lower breast pole, also associated with inferior aesthetic reconstruction and risk of hypertrophic scarring and contracture recurrence. Another option is to release scar and reconstruct the resulting defect on chest wall with skin graft but it also results in contour deformity. However, alternative approaches such as z-plasty, local flap procedures, or tissue expansion have been explored, albeit with varying degrees of success and associated drawbacks, including contracture recurrence and sub-optimal aesthetic results, and risk of hypertrophic scarring.<sup>22</sup>

Patients with extensive abdominal scarring and Younger patients lacking abdominal laxity pose a challenge for pedicle abdominal flap procedures like the transverse rectus abdominis musculocutaneous (TRAM) flap or deep inferior epigastric artery flap from abdomen.<sup>6</sup> Consequently, the latissimus dorsi (LD) flap emerges as a versatile option, although not without drawbacks, including postoperative morbidity, hindrance in daily activities, surgical site seroma, and contour defects on back.

In 2003, Schwabegger et al. introduced the muscle sparing latissimus dorsi (MSLD) flap technique, aiming to preserve LD function while minimizing donor site

morbidity and complications associated with thoracodorsal artery perforator flap.<sup>8,23</sup> Our study corroborates the efficacy of the MSLD flap in addressing IMF contracture and lower pole reconstruction, with superior aesthetic outcomes compared to split-thickness skin grafting. Horizontal or oblique skin paddle designs within natural creases ensure supple coverage and adequate perfusion from descending branch of thoracodorsal artery, thereby mitigating volume deficiencies and projection deformities with minimal risk of contracture recurrence in small to medium sized breasts, however supple tissue envelope is a limiting factor in large sized breasts.

The preservation of LD bulk and function, coupled with enhanced aesthetic outcomes, underscores the growing preference for the MSLD flap in post-burn breast reconstruction. Decreased donor site morbidity, minimal postoperative seroma formation and short hospital stay are added advantages.<sup>24</sup> While bilateral cases often achieve symmetrical results, unilateral burnt breast cases may necessitate additional symmetrizing procedures to optimize outcomes.

Limitations of this study involves lack of symmetrizing procedure to optimize aesthetic outcome. Panel didn't scored best for aesthetic scale due to NAC size and position, extensive scarring in surrounding area of chest and abdomen, surrounding skin rigidity and reconstruction irregularities

## Conclusion

In comparison to thick split-thickness skin grafts, the pedicled muscle-sparing latissimus dorsi flap offers itself as indispensable tool to the arsenal of reconstructive surgeon for post-burn breast reconstruction. This technique provides superior aesthetic results, minimizes the likelihood of contracture recurrence, and involves minimal functional compromise or donor site morbidity. However, split-thickness skin grafts remain a viable option for smaller breasts with simple contractures and less scarring.

**Source of funding:** None

**Conflict of interest:** None

## Author's Contribution

**Dr. Maria Ashraf:** Conception and design of the study, Data collection, Data analysis and interpretation, Final approval of the version to be published and accountable for all aspects of the work in ensuring that questions related to the accuracy or integrity of any part of the

work are appropriately investigated and resolved.

**Dr. Ammara Rabbani:** Concept and design, substantial contribution to acquisition of data, critical review and final approval of the study.

**Dr. Mehwish Ehsan:** Concept and design, substantial contribution to acquisition of data, critical review and final approval of the study.

**Dr. Kamran Khalid:** substantial contribution to acquisition of data, Data analysis and interpretation and final approval of the version to be published

**Dr. Yawwar Sajjad:** acquisition of data, Data analysis and interpretation and final approval of the version to be published

**Dr. Zain Ul Abidin:** contribution to acquisition of data, Data analysis and interpretation and final approval of the version to be published

## References

- Hussein MA, Abdelkader R, El-Henawy AN, Makarem K. Lower Pole Breast Reconstruction Using Muscle-sparing Latissimus Dorsi Flap in Postburn Breast Deformity. *Plast Reconstr Surg Glob Open*. 2021 Sep 22;9(9):e3835. doi: 10.1097/GOX.0000000000003835. PMID: 34584830; PMCID: PMC8460227.
- Nuzzi LC, Cerrato FE, Webb ML, Faulkner HR, Walsh EM, DiVasta AD, Greene AK, Labow BI. Psychological impact of breast asymmetry on adolescents: a prospective cohort study. *Plast Reconstr Surg*. 2014 Dec; 134(6): 1116-1123. doi: 10.1097/PRS.0000000000000736. PMID: 25415081.
- Hudson DA. The Role of the Inframammary Fold (IMF) in Aesthetic and Reconstructive Surgery: A Critical Analysis and Surgical Solution. *Aesthetic Plast Surg*. 2024 Jul;48(14):2663-2667. doi: 10.1007/s00266-023-03729-w. Epub 2023 Nov 13. PMID: 37957392; PMCID: PMC11282132.
- El-Otiefy MA, Darwish AM. Post-burn breast deformity: various corrective techniques. *Ann Burns Fire Disasters*. 2011 Mar 31;24(1):42-5. PMID: 21991241; PMCID: PMC3187946.
- Bayram Y, Sahin C, Sever C, Karagoz H, Kulahci Y. Custom-made approach to a patient with post-burn breast deformity. *Indian J Plast Surg*. 2014 Jan; 47(1): 127-31. doi: 10.4103/0970-0358.129646. PMID: 24987218; PMCID: PMC4075201.
- Gus E, Zhu J, Brooks SG. Postburn breast reconstruction: a scoping review. *Scars Burn Heal*. 2023 Sep 21; 9:20595131231202100. doi: 10.1177/20595131231202100. PMID: 37743873; PMCID: PMC10512695.
- Kunert P, Schneider W, Flory J. Principles and procedures in female breast reconstruction in the young child's burn injury. *Aesthetic Plast Surg*. 1988 May; 12(2): 101-6. doi: 10.1007/BF01576922. PMID: 3389237.
- Schwabegger AH, Harpf C, Rainer C. Muscle-sparing latissimus dorsi myocutaneous flap with maintenance of muscle innervation, function, and aesthetic appearance of the donor site. *Plast Reconstr Surg*. 2003 Apr 1; 111(4): 1407-11. doi: 10.1097/01.PRS.0000049448.56511.23. PMID: 12618599.
- Duraes EFR, Durand P, Morisada M, Scomacao I, Duraes LC, de Sousa JB, Abedi N, Djohan RS, Bernard S, Moreira A, Schwarz GS. A Novel Validated Breast Aesthetic Scale. *Plast Reconstr Surg*. 2022 Jun 1; 149(6): 1297-1308. doi: 10.1097/PRS.00000000000009156. Epub 2022 Mar 29. PMID: 35349538.
- Jain V, Gupta J, Gupta N, Jain P. Alteration in gene expression of transforming growth factor- $\beta$  following treatment of hypertrophic burn scars with three different therapeutic modalities. *International Journal of Medical and Biomedical Studies*. 2019;3.
- Atiyeh B, Fadul R, Habr N, Chahine F. Simplified planning and marking of mastopexy and reduction mammoplasty: the circumvertical "Matryoshka" pattern. *Rev. Bras. Cir. Plást*. 2021;36(4):407-416
- Mousavizadeh SM, Motamed S, Hosseini SN, Yavari P. Re-creation of the Inframammary Fold, Breast Mound, and Projection by the Latissimus Dorsi Musculocutaneous Flap in Burned Breasts. *Eplasty*. 2011 Feb 24;11:e11. PMID: 21369368; PMCID: PMC3045114.
- Saint-Cyr M, Nagarkar P, Schaverien M, Dauwe P, Wong C, Rohrich RJ. The pedicled descending branch muscle-sparing latissimus dorsi flap for breast reconstruction. *Plast Reconstr Surg*. 2009 Jan;123(1):13-24. doi: 10.1097/PRS.0b013e3181934838. PMID: 19116510.
- Nahabedian MY, Neligan PC. *Plastic surgery: Volume 5: breast*. Elsevier Health Sciences; 2017 Aug
- Masud S, Hyder AA, Khan UR, Khan NU, Petrucka P. Epidemiology and perceptions of non-fatal burns among select youth (15-24 years old) from Peshawar Pakistan; a sequential explanatory mixed methods study. *Burns Open*. 2024 Apr;8(2):60-67. doi: 10.1016/j.burnso.2024.01.003. Epub 2024 Jan 17. PMID: 39238651; PMCID: PMC11376268.
- Siddiqui E, Zia N, Feroze A, Awan S, Ali A, Razzak J, Hyder AA, Latif A. Burn injury characteristics: findings from Pakistan National Emergency Department Surveillance Study. *BMC Emerg Med*. 2015;15 Suppl 2 (Suppl 2):S5. doi: 10.1186/1471-227X-15-S2-S5. Epub 2015 Dec 11. PMID: 26692165; PMCID: PMC4682377.

18. Grishkevich VM. Restoration of the shape, location and skin of the severe burn-damaged breast. *Burns*. 2009 Nov;35(7):1026-35. doi: 10.1016/j.burns.2008.12.008. Epub 2009 May 5. PMID: 19409709.
19. Arabi Z, Md Monoto EM, Bojeng A. Impact of childhood burn injuries on breastfeeding: a case report. *Int Breastfeed J*. 2019 Apr 18;14:17. doi: 10.1186/s13006-019-0210-4. PMID: 31019544; PMCID: PMC6472062.
20. Tugertimur B, Dec W. Deep Inferior Epigastric Artery Perforator Flap Reconstruction for Breast Burn Deformities. *Plast Reconstr Surg Glob Open*. 2020 Jul 14; 8(7):e2981. doi: 10.1097/GOX.0000000000002981. PMID: 32802672; PMCID: PMC7413775.
21. Gronovich Y, Maisel Lotan A, Retchkiman M. Post-burn breast reconstruction using an artificial dermis-a long-term follow-up. *Burns Trauma*. 2016 Jul 4;4:12. doi: 10.1186/s41038-016-0037-9. PMID: 27574682; PMCID: PMC4964029.
22. Jarjis RD, Matzen SH. Release and Reconstruction of a Postburn Deformed Breast in a Young Woman. *Plast Reconstr Surg Glob Open*. 2016 Mar 17;4(3):e643. doi: 10.1097/GOX.0000000000000626. PMID: 27257573; PMCID: PMC4874287.
23. Colohan S, Wong C, Lakhiani C, Cheng A, Maia M, Arbique G, Saint-Cyr M. The free descending branch muscle-sparing latissimus dorsi flap: vascular anatomy and clinical applications. *Plast Reconstr Surg*. 2012 Dec;130(6):776e-787e. doi: 10.1097/PRS.0b013e31826d9c5e. PMID: 23190829.
24. Sowa Y, Numajiri T, Nakatsukasa K, Sakaguchi K, Taguchi T. Comparison of morbidity-related seroma formation following conventional latissimus dorsi flap versus muscle-sparing latissimus dorsi flap breast reconstruction. *Ann Surg Treat Res*. 2017 Sep; 93(3): 119-124. doi: 10.4174/ast.2017.93.3.119. Epub 2017 Aug 30. PMID: 28932726; PMCID: PMC5597534.

## Research Article

### Effects of Enteral Albumin on Healing of Laser Doppler Determined Superficial Partial Thickness Fresh Flame Burns of Adults

Afzaal Bashir,<sup>1</sup> Sunaina Afzaal,<sup>2</sup> Salman Ali,<sup>3</sup> Hajra Ahmad,<sup>4</sup> Mohammed A. Alharbi,<sup>5</sup> Sunniya Afzaal<sup>6</sup>

<sup>1</sup>Department of Plastic Surgery, Allama Iqbal Medical College, Lahore, <sup>2-3</sup>Punjab Rangers Teaching Hospital, Lahore;

<sup>4</sup>Department of Environmental Design, Health and Nutritional Sciences, Allama Iqbal Open University, Islamabad;

<sup>5</sup>King Abdullah Medical City, Makkah, Saudia Arabia, <sup>6</sup>Shalama Medical and Dental College, Lahore,

#### Abstract

**Background:** Burn wounds have different injury levels which affects their healing potential. Along with wound care, burns healing requires additional macro and micronutrients to cope with high catabolic state. Albumin is one of the important macromolecule in this healing process.

**Objective:** The aim of this study is to define the role of albumin in healing of superficial partial thickness fresh flame burn wounds.

**Methodology:** This prospective double-blinded randomized control study was conducted from February 2019 to January 2020 in Mayo Hospital Burn Center, Lahore, Pakistan. One hundred adult patients of fresh flame burns having superficial partial thickness wounds which were assessed clinically and objectively determined by Laser Doppler Imaging were randomly allocated into supplemented albumin group (SAG) and non-supplemented albumin group (NSAG). Oral dietary supplementation by albumin 2g/kg body weight was given and outcomes were compared in terms of hospital stay, serum albumin at 7th day, number of dressings, mean pain score during first week of treatment and approximate cost.

**Results:** Mean age of the patients was 33±9.2. In SAG, mean hospital stay was 10(2.9) days, mean number of interactive dressings required were 2(1.3), mean pain score during first week was 4(1.7) and mean cost of treatment was 339(23) USD while in NSAG, mean hospital stay was 19(3.7), mean number of interactive dressings 4(1.7), mean pain score during first week 7(1.3) and mean cost was 522(70) USD.

**Conclusion:** Supplementation with oral albumin in acute burn management leads to quicker wound healing, less frequency of dressing change, lesser pain and decreased costs.

**Received** | 25-11-2024 **Revision** | 10-12-2024 **Accepted** | 11-01-2025

**Corresponding Author** | Dr. Afzaal Bashir, Associate Professor, Department of Plastic Surgery, Allama Iqbal Medical College, Lahore. **Email:** dr.afzaal@yahoo.com

**Keywords** | Albumin, Superficial Partial Thickness Burn, Laser Doppler Imaging, Pain Score, Hospital Stay, Interactive dressing

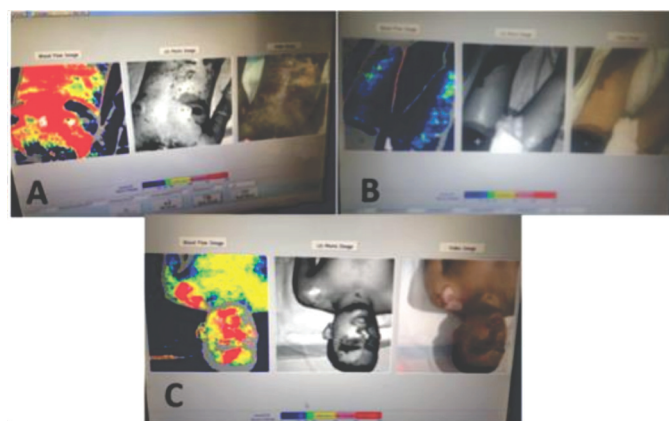
#### Introduction

Burn injuries are a global public health problem with physical, psychological, social and economic implications resulting in insult to body tissues particularly the skin causing coagulative necrosis due to extreme temperature, electricity or chemicals.<sup>1,2</sup> No one is immune to burn injuries but adults of actively working age group (18 - 40 years) are more susceptible. Flame

burns are the most common variety occurring at domestic as well as workplace incidences.<sup>3</sup> Depending on depth, we can classify burn wounds into superficial, superficial partial thickness, deep partial thickness and full thickness burns.<sup>4</sup> Knowledge of wound thickness in burns is mandatory as it helps in deciding the type of treatment needed ranging from ointments, interactive dressings, antibiotics and surgical techniques. Depth determination

is not only essential for making decisions regarding management but also its clinical estimation is a challenging task.<sup>5</sup> Laser Doppler Imaging is one of the latest gadgets which objectively determines burn tissue thickness as an adjunct to clinical diagnosis and gives pictures having red, yellow and blue color based on vascularity of the burned skin as shown in Fig 1.<sup>4</sup> Red color shows superficial partial thickness wound (normal vascularity), yellow indicates deep partial thickness (inadequate vascularity) and blue color shows full thickness wound (no vascularity). Patients having superficial partial thickness burn wounds are the group of particular interest in burn centers due to two reasons. Firstly, the majority of burn injuries fall in this group and secondly, these are the wounds which, if managed well, heal within three weeks satisfactorily without any surgical intervention.<sup>6</sup>

Nutrition has very vital role in burn wound healing.<sup>7</sup> Early enteral nutritional support in the form of both micronutrients and macronutrients not only provides metabolic ingredients for wound healing but also protects against curling ulcers and trans-migration of bacteria from gut mucosa.<sup>8</sup> Albumin is an important component of dietary proteins. It is also one of the major proteins in our plasma playing vital role as a carrier of different substance in the blood and maintenance of plasma colloid osmotic pressure.<sup>9</sup> Decrease in plasma albumin level is commonly found in burns due to loss through wound surface and decreased synthesis in hypercatabolic state.<sup>10</sup> Hypoalbuminemia resulted in plasma water to migrate into interstitial tissues leading to tissue edema and ultimately delayed wound healing.<sup>11</sup> Intravenous albumin infusions are needed to correct plasma albumin levels, which are not only costly but also associated with severe anaphylactic reactions mandating cautious monitoring. Contrast to it, dietary albumin can be easily had from poultry eggs and does not cause any significant reaction.<sup>12</sup> After digestion, dietary albumin provides basic amino acids as building block for wound healing and also for de-novo synthesis of plasma albumin to maintain its certain level in blood which can help in healing of burn wounds.<sup>11</sup> The rationale of this study was to find out role of dietary albumin in healing of superficial partial thickness burns after determining wound thickness clinically and as well as by laser doppler imaging to enhance the accuracy so that effect of dietary albumin can be properly emphasized in the best interest of better wound care.



**Figure 1:** LDI of Burn Wounds. **A.** Red color on LDI shows superficial partial thickness, **B.** Blue color on LDI shows full thickness, **C.** Yellow color on LDI shows Deep Partial thickness

### Methodology

In this double blinded randomized control trial, 100 adult patients were recruited from Burn Center, Mayo Hospital/King Edward Medical University, Lahore, Pakistan from February 2019 to January 2020 who were having 10% to 20% of total body surface area with superficial partial thickness burn presenting within 24 hours of the incident. Area of burn was calculated by Wallace rule of nine and depth was determined subjectively by clinical examination as well as objectively by Laser Doppler Imaging as adjunct.<sup>6</sup> Patients with BMI below 18.9 or above 24.9 and those with abnormal serum albumin at admission were not considered for the study due to comorbidities associated with abnormal BMI. Similarly, patients with known allergy to albumin, having any metabolic disorder and/or uncontrolled co-morbidity (i.e. DM, HTN, CRF, CCF, CLD) were excluded.<sup>13</sup> Patients who were put on nil per oral (NPO) or refused to take diet from hospital kitchen were also excluded.<sup>14</sup>

The patients were randomly allocated into two groups, Supplemented Albumin (SA) group and Non-Supplemented Albumin (NSA) group, each containing 50 patients. Isonitrogenous and isocaloric diet prepared in hospital's kitchen with basic composition given in Table 1 was provided to all patients with calories according to Curreri Formula:  $(25\text{kcal})(\text{weight in Kg}) + (40\text{kcal})(\% \text{body surface area burned})$ .<sup>15</sup> All patients were exclusively fed enterally and energy composition was used as 48% from carbohydrate, 41% from fat and 11% from proteins.<sup>16</sup> In addition, SA group also received supplemental enteral Albumin 2g per kilogram body weight per day in two divided

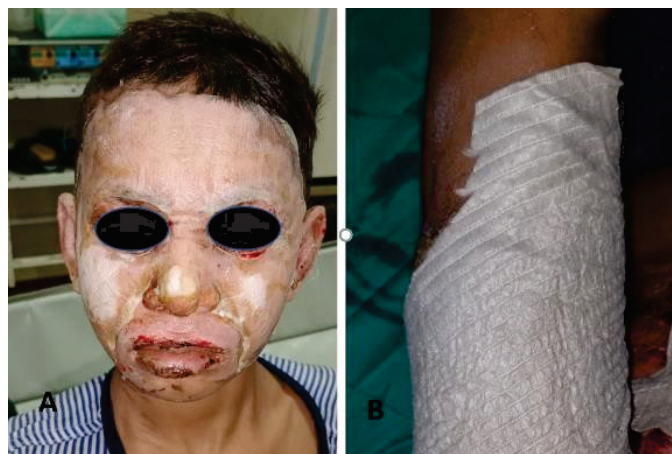doses in the form of boiled egg white from the time of admission to discharge from hospital.<sup>17,18</sup> So the diets of two groups differed only in albumin level. Patients and investigators were blinded to type of diet with respect to supplementation.

**Table 1:** Dietary composition provided by hospital kitchen feed

Components	Amount in 100gm
<b>Calories (kcal)</b>	488
Macronutrients	58.4
Carbohydrates (g)	
<b>Proteins (g)</b>	13.2
Lipids (g)	22.4
Micronutrients	
<b>Vitamins</b>	
A (µg retinol equivalent)	419.7
C (mg)	97.6
D (µg)	9.0
E (mg tocopherol equivalent)	12.0
Thiamin (mg)	1.0
Riboflavin (mg)	1.2
Niacin (mg)	10.0
B6 (mg)	1.1
K1 (µg)	52.5
Inositol (mg)	24.4
Pantothenic Acid (mg)	3.7
Folic Acid (µg)	104.4
Minerals/Elements	
Sodium (mg)	195.2
Potassium (mg)	595.4
Chlorine (mg)	439.2
Iron (mg)	6.3
Calcium (mg)	439.2
Phosphorus (mg)	341.6
Magnesium (mg)	73.2
Zinc (mg)	6.3
Copper (mg)	0.5
Iodine (µg)	49.1
Selenium (µg)	14.7
Molybdenum (µg)	14.6
Manganese (mg)	0.8
Chromium (µg)	15.0

Burn wound management in both SA and NSA groups was done by the same surgical team under standard guidelines of burn wound care including resuscitation, pain relief, antibiotics and interactive silver dressing on all wounds except face where hydrogel dressing was applied to avoid silver induced pigmentation as shown in fig 2. Interactive silver impregnated dressing done for other wounds was assessed by inspection on daily basis for soakage due to oozing from wound and was immediately changed if more than 25% of the dressing

area was soaked.<sup>19</sup> Outer covering of the dressing was removed on every other day and integrity of the wound dressing was assessed. Dressing easily fell off once the wound was complete epithelized.<sup>20</sup> Epithelization was further confirmed on clinical examination by consultant plastic surgeon. Further dressing of the wound was stopped and day of hospitalization was noted. Patients were discharged from hospital with advice to apply emollient on epithelized surface at home and visit for follow up. Pain was managed by intravenous acetaminophen and nalbuphine according to body weight and pain scoring was done by grading from one to ten by the patient every time before giving dose of analgesia.<sup>21</sup> Mean pain score was calculated at the end of 7<sup>th</sup> day. Serum albumin was assessed at the time of recruitment as well as at 7<sup>th</sup> day. Approximate treatment cost was calculate in Pakistani rupees and then converted into US dollar on latest market value. It included calculated cost of medications, dressings and nutrition while hospital charges and staff salaries were not included because Mayo Burn unit belongs to public sector hospital. The study protocol was reviewed and approved by the institutional review board and trial was registered at Clinical Trial Registry under registration number NCT03709069.



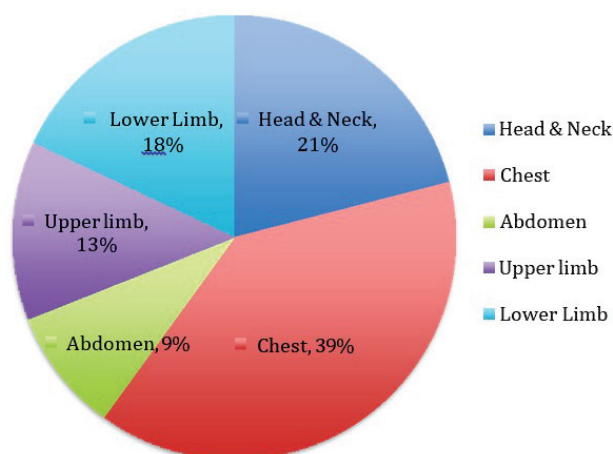
**Figure 2:** A) Hydrogel Dressing on Face B) Silver dressing applied on superficial partial thickness burn wound of forearm

Qualitative variables like gender, regions of body involved and primary cause of burn were expressed in proportion while quantitative variable like age, percentage body surface area burnt, body mass index at admission, serum albumin level, mean pain score during first week, total calories taken per day, number of dressings, hospital stay in days and approximate cost of treatment in US dollars were expressed as means (SD). Data analysis was done by using SPSS 21. Independent sample

t-test was applied to mean pain score during first week, hospital stay, number of dressings and approximate cost of treatment. The p-value  $< 0.05$  was considered statistically significant.

### 3. Results

One hundred patients were managed for their superficial partial thickness fresh flame burn wounds with 50 patients in each SA group and NSA group. Regions of the body involved by burn were head and neck in 21% cases, chest 39%, abdomen 9%, upper limb 13% and lower limb in 18% cases as represented in figure 3.



**Figure 3:** Regions of body involved

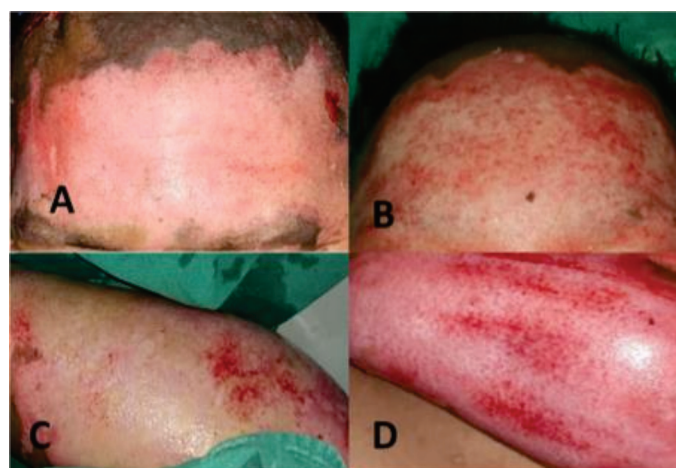There was no significant difference between two groups regarding age, sex ratio, serum albumin at admission, BMI and burn surface area. All patients were exclusively fed on enteral diet. Real intake average was about 93% with no remarkable difference between SA (92%) and NSA (95%) group as given in Table 2.

**Table 2:** Population characteristics of two groups at recruitment

Character	SA Group	NSA Group
Age (Years)	33.5 (24 - 41)	32.7 (25 - 39)
BMI	21.3 (19 - 23)	21.7 (18.7 - 23.2)
Body Area Burn (%)	15.3 (11 - 19)	14.9 (11 - 18)
Serum Albumin at admission	4.7 (4.2 - 5.1)	4.7 (4.1 - 5.2)
Average kcal/day	2270.20 (170)	2310 (150)

Average kilo calories consumed per day by patients of SA group were 2270.20Kcal/day (170) while in NSA group average kilo calories consumed were 2310 (150). In SA group, enteral supplementation of Albumin was done 2 gram per kilogram body weight per day and ranged from 110 to 170 grams with mean of 127.20 (10.50) given in two divided doses. Serum albumin level at 7<sup>th</sup> post admission day was significantly better

in SA group with average of 5.1 (1.7) g/dl than in NSA group with average of 3.9 (0.7) g/dl, repeated measure ANOVA showed  $p < 0.05$ . In patients of SA group, 64% required only two dressings to get complete healing of their burn wounds, 14% required three, 18% required four, 2% required five and 2% required six dressings. Mean number of interactive dressings required were 2 (1.3). In patients of NSA group, 6% required two dressings to get complete healing of their burn wounds, 22% required three, 50% required four, 16% required five and 6% required six dressings. Mean number of interactive dressings required were 4 (1.7).



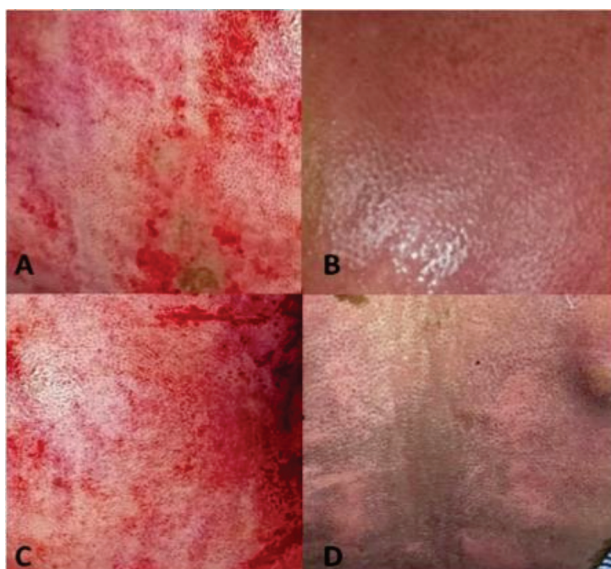
**Figure 4:** Representative patient of NSA group

Hospital stay in SA group was less than ten days in 86%, eleven to fifteen days in 8% and in 6% it was more than fifteen days while mean hospital stay was 10 (2.9) days. In NSA group, hospital stay was less than ten days in 22%, eleven to fifteen days in 62% and in 16% it was more than fifteen days. Mean hospital stay was 19 (3.7) days. In SA group, average pain score during first week of treatment was less than 4 in 44% patients, between 5 to 7 in 54% patients and more than 7 in 2% patients with mean pain score during first week of treatment was 4 (1.7). Average pain score in NSA group during first week of treatment was less than 4 in 4% patients, between 5 to 7 in 90% patients and more than 7 in 6% patients with mean pain score during first week was 7 (1.3). Approximate mean cost of treatment in SA group was 339 (23) USD per patient while in NSA group it was 522 (70) USD per patient. Student's t test was used to find out significance of differences between SA and NSA groups in number of dressings, hospital stay, mean pain score in first week and approximate cost which showed  $p < 0.05$ . Comparison of the two groups is shown in Table 3. Representative patients of NSAG and SAG groups are shown in fig 4&5 respectively.

Burn wound healing in two weeks in Non supplemented Albumin group. A. Forehead burn wound at admission B. Partially epithelized after two weeks C. Arm burn wound at admission D. Partially epithelized after two weeks.

**Table 3:** comparison of outcomes between SA and NSA groups

	SA Group	NSA Group
Mean Number of Dressings	2 (1.3)	4 (1.7)
Mean pain score during first week	4 (1.7)	7 (1.3)
Serum Albumin at 7 <sup>th</sup> admission day	5.1 (1.7)	3.9 (0.7)
Mean Hospital Stay (Days)	10 (2.9)	19 (3.7)
Approximate Cost in USD	339 (23)	522 (70)



**Figure 5:** Burn wound healing in two weeks in Supplemented Albumin (SA) group. A&B. Burn wound on anterior abdominal wall at admission & Completely epithelized after two weeks, C&D. Burn wound at back of Torso at admission & Completely epithelized after two weeks

## Discussion

Burn management not only requires wound care but nutritional support is also mandatory to combat the hyper-metabolic state in burns.<sup>22</sup> To speed up healing process in burns, many studies have proposed different dietary supplementing agents.<sup>16,23</sup> The present study is peculiar in the way that it estimates benefits of albumin supplementation in burn wound management by prospective double blind randomized clinical trial using isocaloric diet.

BMI is considered to be a good predictor of fitness and healing.<sup>24</sup> It is also used as tool for assessing previous nutritional status of the patient.<sup>25</sup> Like most of other studies, its confounding effects were taken into account

in our study as well. All the patients selected were having BMI in normal range. In most of the studies, burn depth has been determined by clinical examination which is highly observer dependent based on skill and practice.<sup>4,26</sup> Despite of managing burn injuries for years, clinical estimation of burn depth is not accurate and it has been noticed to be highly varied assessment from surgeon to surgeon. Laser Doppler is an adjunct to objectively help in determining the burn thickness so it has been employed in this study to segregate superficial partial thickness burn wounds from other classes of burns to emphasize the effect of albumin supplementation on uniform population of burn wounds.<sup>27</sup> This method has so far not been used in any of the currently published study to determine depth of burn for effect of nutrition elements particularly albumin.

Interactive dressings are considered as reliable and easy remedy for burn wounds.<sup>19</sup> These dressings have anti-microbial role and absorb ooze from the wound surface as a result of which no frequent change of dressing is needed until it is soaked.<sup>28</sup> Silver impregnated dressings as recommended by many studies are considered as icon of burn management.<sup>29</sup> Albumin has 585 amino acids and is easily available from poultry source.<sup>14</sup> Administration of albumin through enteral route is very easy without any special arrangement due to non-toxicity of over dosage.<sup>30</sup> Role of albumin on healing of burn wounds may be rendered to its specific amino acid variety and number. Supplementation by albumin improves healing potential of burn wounds by providing amino acids for maintaining level of serum albumin and compensating its loss through oozing from burn wound.<sup>31</sup> Maintained level of serum albumin also decreases tissue edema which is also an adjunct of healing.<sup>32</sup> As described in other studies, fall in serum albumin leads to poor wound healing as it results in tissue edema and in SA group serum albumin levels were well maintained particularly at seventh day as compared to NSA group.<sup>33</sup> Similarly, SA group patients were having low stretching of tissues by oedema and resulted in decreased pain as in NSA group. We found mean pain score during first week of treatment was interestingly lesser in population of SA group patients as compared to NSA patients.<sup>34</sup> Dressing soakage leading to dressing change was far less in SA group patients than in NSA group which was expected as proposed in other studies.<sup>35</sup>

As proposed by some studies that less tissue oedema due to intravenous albumin enhances healing process in burn patients but, unlike our study, none of them established the effect of oral albumin supplementation

on burn wound healing as we have seen in SA group patients.<sup>36</sup> In this study, dosage of albumin supplemented was 2 grams per kilograms body weight but the exact mechanism that how varied dose of albumin will affect healing process needs further studies.

This study had a limitation as most of the burn wounds are of mixed thickness. So we considered only those patients in which the most part of wound (> 90%) was superficial partial thickness clinically as well as shown in red color by LDI. Furthermore, due to limited oral intake of albumin, only burns with 10 to 20% body surface area involved were considered which may pave the way for more extensive burns in further studies.

### Conclusion:

Supplementation of nutrition with albumin in acute burn management has no adverse effects and leads to faster wound healing, lesser analgesia demand, lesser wound care required to achieve burn wound healing short hospital stay and decreased economic burden.

**Conflict of interest:** None

**Source of funding:** None

### Authors contribution

**Dr. Afzaal Bashir:** Conception and design of the study, Drafting the work, analysis and interpretation, data collection, Final approval of the version to be published and accountable for all aspects of the work in ensuring that questions related to the accuracy or integrity of any part of the work are appropriately investigated and resolved.

**Dr. Sunaina Afzaal:** Study design, drafting of work, Data Collection and analysis and interpretation

**Dr. Salman Ali:** Conception and design of the study, critical revision of the article and final approval of the article to be published

**Hajra Ahmad:** Data collection, Article Editing, Manuscript Revision, analysis and interpretation of data

**Dr. Mohammed A. Alharbi:** Article Editing, Manuscript Revision analysis and interpretation of data

**Sunniya Afzaal:** Data Collection, critical revision of the article and final approval of the article to be published

### References

1. Bashir A, Bashir MM, Sohail M, Imran M, Mahek L, Afzaal S. Changes in anxiety level of females with facial lesions before and after plastic surgery. *Int J Public Health Clin Sci*. 2019;6(2):151-9.
2. Jeschke MG, van Baar ME, Choudhry MA, Chung KK, Gibran NS, Logsetty S. Burn injury. *Nat Rev Dis Primers*. 2020 Feb 13;6(1):11. doi: 10.1038/s41572-020-0145-5. PMID: 32054846; PMCID: PMC7224101.
3. Abazari M, Ghaffari A, Rashidzadeh H, Badeleh SM, Maleki Y. A Systematic Review on Classification, Identification, and Healing Process of Burn Wound Healing. *Int J Low Extrem Wounds*. 2022 Mar;21(1):18-30. doi: 10.1177/1534734620924857. Epub 2020 Jun 11. PMID: 32524874.
4. Jan SN, Khan FA, Bashir MM, Nasir M, Ansari HH, Shami HB, Nazir U, Hanif A, Sohail M. Comparison of Laser Doppler Imaging (LDI) and clinical assessment in differentiating between superficial and deep partial thickness burn wounds. *Burns*. 2018 Mar;44(2):405-413. doi: 10.1016/j.burns.2017.08.020. Epub 2017 Sep 14. PMID: 28918904.
5. Karim AS, Yan A, Ocotl E, Bennett DD, Wang Z, Kendzierski C, Gibson ALF. Discordance between histologic and visual assessment of tissue viability in excised burn wound tissue. *Wound Repair Regen*. 2019 Mar; 27(2): 150-161. doi: 10.1111/wrr.12692. Epub 2018 Dec 26. PMID: 30585657; PMCID: PMC6393178.
6. Yildirim R, Guner A, Cekic AB, Usta MA, Ulusahin M, Turkyilmaz S. Outcomes of the Use of Hyaluronic Acid-Based Wound Dressings for the Treatment of Partial-Thickness Facial Burns. *J Burn Care Res*. 2023 May 2;44(3):551-554. doi: 10.1093/jbcr/irz004. PMID: 30715375.
7. Nunez JH, Clark AT. Burn Patient Metabolism and Nutrition. *Phys Med Rehabil Clin N Am*. 2023 Nov; 34(4):717-731. doi: 10.1016/j.pmr.2023.06.001. Epub 2023 Jul 6. PMID: 37806693.
8. Yang X, Li R, Zhai J, Fan Y, Gong S, Li L, Nie X, Li W. Effects of early enteral nutrition in patients with severe burns: A systematic review. *Medicine (Baltimore)*. 2024 Feb 16;103(7):e37023. doi: 10.1097/MD.00000000037023. PMID: 38363893; PMCID: PMC10869067.
9. van de Wouw J, Joles JA. Albumin is an interface between blood plasma and cell membrane, and not just a sponge. *Clin Kidney J*. 2021 Oct 5;15(4):624-634. doi: 10.1093/ckj/sfab194. PMID: 35371452; PMCID: PMC8967674.
10. Jaber CA, Bryan FE, Toor RS, Quereshi AM, Messer TA, Schlanser VL, Tatebe LC, Poulakidas SJ, Bokhari F. Initial Laboratory Values Can Predict Mortality in Burn Patients. *Am Surg*. 2023 Dec;89(12):5156-5160. doi: 10.1177/00031348221083945. Epub 2022 Nov 8. PMID: 36346123.
11. de Tymowski C, Pallado S, Anstey J, Depret F, Moreno N, Benyamina M, Cupaciu A, Jully M, Oueslati H, Fratani A, Coutrot M, Chaussard M, Guillemet L, Dudoignon E, Mimoun M, Chaouat M, Mebazaa A, Legrand M, Soussi S; PRONOBURN group. Early hypoalbuminemia is associated with 28-day mortality in severely burned patients: A retrospective cohort study. *Burns*. 2020 May;46(3):630-638. doi: 10.1016/j.burns.2019.09.013. Epub 2019 Oct 16. PMID: 31629616.

12. Maurya SK, Asthana A, Maurya SP, Maurya P, Maurya A. Qualitative analysis of protein: Egg albumin and milk. *Indian J Drugs*. 2019;7(1):30-3.
13. Azoury ME, Fili L, Bechara R, Scornet N, de Chaise-martin L, Weaver RJ, Claude N, Maillere B, Parronchi P, Joseph D, Pallardy M. Identification of T-cell epitopes from benzylpenicillin conjugated to human serum albumin and implication in penicillin allergy. *Allergy*. 2018 Aug;73(8):1662-1672. doi: 10.1111/all.13418. Epub 2018 Feb 27. PMID: 29355985.
14. Kheiridoosh F, Kashanian S, Khodaei MM, Sariaslani M, Falsafi M, Moghadam NH, Salehzadeh S, Pazhavand M, Kashanian M. Spectroscopic studies on the interaction of aspartame with human serum albumin. *Nucleosides Nucleotides Nucleic Acids*. 2021;40(3):300-316. doi: 10.1080/15257770.2021.1872792. Epub 2021 Jan 16. PMID: 33455539.
15. Jeon J, Kym D, Cho YS, Kim Y, Yoon J, Yim H, Hur J, Chun W. Reliability of resting energy expenditure in major burns: Comparison between measured and predictive equations. *Clin Nutr*. 2019 Dec;38(6):2763-2769. doi: 10.1016/j.clnu.2018.12.003. Epub 2018 Dec 8. PMID: 30579670.
16. Linden MA, Teixeira TLM, Freitas RGBON, Brandão MÂB, Nogueira RJN. Arginine and glutamine supplementation on transthyretin levels in severely burned patients: A systematic review. *Nutrition*. 2022 Sep;101:111657. doi: 10.1016/j.nut.2022.111657. Epub 2022 Mar 20. PMID: 35653933.
17. Corsetti G, Pasini E, Scarabelli TM, Romano C, Singh A, Scarabelli CC, Dioguardi FS. Importance of Energy, Dietary Protein Sources, and Amino Acid Composition in the Regulation of Metabolism: An Indissoluble Dynamic Combination for Life. *Nutrients*. 2024 Jul 25;16(15):2417. doi: 10.3390/nu16152417. PMID: 39125298; PMCID: PMC11313897.
18. Levitt DG, Levitt MD. Human serum albumin homeostasis: a new look at the roles of synthesis, catabolism, renal and gastrointestinal excretion, and the clinical value of serum albumin measurements. *Int J Gen Med*. 2016 Jul 15;9:229-55. doi: 10.2147/IJGM.S102819. PMID: 27486341; PMCID: PMC4956071.
19. Weller C, V Team. Interactive dressings and their role in moist wound management. In: *Advanced textiles for wound care*. 2019. p.105-34.
20. Rezvani Ghomi E, Niazi M, Ramakrishna S. The evolution of wound dressings: From traditional to smart dressings. *Polym Adv Technol*. 2023;34(2):520-30.
21. McGovern C, Puxty K, Paton L. Major burns: part 2. Anaesthesia, intensive care and pain management. *BJA Educ*. 2022 Apr;22(4):138-145. doi: 10.1016/j.bjae.2022.01.001. Epub 2022 Feb 8. PMID: 35531075; PMCID: PMC9073309.
22. Houschyar M, Borrelli MR, Tapking C, Puladi B, Ooms M, Maan ZN, et al. The hypermetabolic response to burns and its treatment: A literature review. *Curr Nutr Food Sci*. 2023;19(7):682-91.
23. Daher GS, Choi KY, Wells JW, Goyal N. A Systematic Review of Oral Nutritional Supplement and Wound Healing. *Ann Otol Rhinol Laryngol*. 2022 Dec; 131(12): 1358-1368. doi: 10.1177/00034894211069437. Epub 2022 Jan 19. PMID: 35043693.
24. Al-Dolaimy F, Abdul-Reda Hussein U, Hadi Kzar M, Saud A, Abed Jawad M, Yaseen Hasan S, Alhassan MS, Hussien Alawadi A, Alsaalamy A, Farzan R. Relationship between body mass index and mortality of burns patients: A systematic review and meta-analysis. *Int Wound J*. 2024 Jan;21(1):e14358. doi: 10.1111/iwj.14358. Epub 2023 Sep 1. Retraction in: *Int Wound J*. 2025 Mar;22(3):e70290. doi: 10.1111/iwj.70290. PMID: 37654247; PMCID: PMC10781895.
25. Walger ACV, Cardoso LTQ, Tanita MT, Matsuo T, Carrilho AJF, Grion CMC. The Impact of Body Mass Index in Patients with Severe Burn Injury. *Eur Burn J*. 2022 Aug 22;3(3):425-431. doi: 10.3390/ebj3030037. PMID: 39599956; PMCID: PMC11571838.
26. Żwierzeło W, Piorun K, Skórka-Majewicz M, Maruszewska A, Antoniewski J, Gutowska I. Burns: Classification, Pathophysiology, and Treatment: A Review. *Int J Mol Sci*. 2023 Feb 13;24(4):3749. doi: 10.3390/ijms24043749. PMID: 36835171; PMCID: PMC9959609.
27. Wearn C, Lee KC, Hardwicke J, Allouni A, Bamford A, Nightingale P, Moiemmen N. Prospective comparative evaluation study of Laser Doppler Imaging and thermal imaging in the assessment of burn depth. *Burns*. 2018 Feb;44(1):124-133. doi: 10.1016/j.burns.2017. 08.004. Epub 2017 Oct 9. PMID: 29032974.
28. Lei J, et al. The wound dressings and their applications in wound healing and management. *Health Sci J*. 2019; 13(4):1-8.
29. Paladini F, Pollini M. Antimicrobial Silver Nanoparticles for Wound Healing Application: Progress and Future Trends. *Materials (Basel)*. 2019 Aug 9;12(16):2540. doi: 10.3390/ma12162540. PMID: 31404974; PMCID: PMC6719912.
30. Hashem L, Swedrowska M, Vllasaliu D. Intestinal uptake and transport of albumin nanoparticles: potential for oral delivery. *Nanomedicine (Lond)*. 2018 Jun; 13(11): 1255-1265. doi: 10.2217/nnm-2018-0029. PMID: 29949465.
31. Fitriansyah I, Djanas D, Bachtiar H. The effect of oral albumin intake on serum albumin levels in preeclampsia patients with hypoalbuminemia in RSUP Dr. M. Djamil Padang. *Andalas Obstet Gynecol J*. 2021;5(1):69-81.

32. Zdolsek M, Hahn RG, Zdolsek JH. Recruitment of extravascular fluid by hyperoncotic albumin. *Acta Anaesthesiol Scand*. 2018 Oct;62(9):1255-1260. doi: 10.1111/aas.13150. Epub 2018 May 29. PMID: 29845612.
33. Bandeira NG, Barroso MVVS, Matos MAA, Filho ALM, Figueredo AA, Gravina PR, Klein SOT. Serum Albumin Concentration on Admission as a Predictor of Morbidity and Mortality in Patients With Burn Injuries. *J Burn Care Res*. 2021 Sep 30;42(5):991-997. doi: 10.1093/jbcr/irab004. PMID: 33481997.
34. Mojsa IM, Pokrowiecki R, Lipczynski K, Czerwonka D, Szczeklik K, Zaleska M. Effect of submucosal dexamethasone injection on postoperative pain, oedema, and trismus following mandibular third molar surgery: a prospective, randomized, double-blind clinical trial. *Int J Oral Maxillofac Surg*. 2017 Apr;46(4):524-530. doi: 10.1016/j.ijom.2016.11.006. Epub 2016 Dec 21. PMID: 28012633.
35. Zdolsek M, Hahn RG, Sjöberg F, Zdolsek JH. Plasma volume expansion and capillary leakage of 20% albumin in burned patients and volunteers. *Crit Care*. 2020 May 5;24(1):191. doi:10.1186/s13054-020-02855-0. PMID: 32366324; PMCID: PMC7199306.
36. Abazari M, Ghaffari A, Rashidzadeh H, Badeleh SM, Maleki Y. A Systematic Review on Classification, Identification, and Healing Process of Burn Wound Healing. *Int J Low Extrem Wounds*. 2022 Mar; 21(1):18-30. doi: 10.1177/1534734620924857. Epub 2020 Jun 11. PMID: 32524874

## Case Report

### A Terrifying Pediatric Impalement Injury of the Hand

Muhammad Imran Khan,<sup>1</sup> Asma Sarfaraz,<sup>2</sup> Hassan Tahir,<sup>3</sup> Namia Cho<sup>4</sup>

<sup>1-4</sup>Department of plastic and reconstructive surgery, Liaquat National Hospital, Karachi.

#### Abstract

Impalement injuries are rare injuries which may result from penetration of any foreign object into an individual. Manly two modes of injuries are reported. We report a case resulting from a child falling on an immobile object, the fence over the wall penetrating the left hand. Such injuries require careful inspection gentle handling and immediate transfer to an expert in emergency centre. In our case the injury was successfully managed with uneventful recovery.

Received | 28-10-2024 Accepted | 01-01-2025

**Corresponding Author** | Hassan Tahir, Department of plastic and reconstructive surgery, Liaquat National Hospital, Karachi

**Email:** h.tahir1992@gmail.com

**Keywords** | Pediatric impalement, hand trauma, rail spike, foreign body

#### Introduction

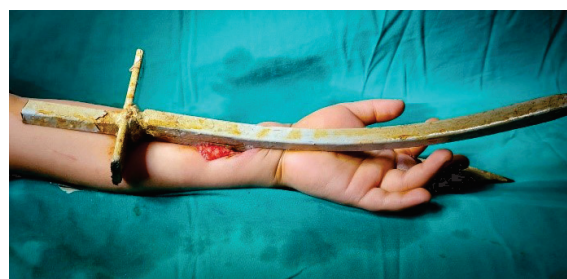Impalement injuries are rare wounds resulting from a foreign object which penetrates an individual<sup>(1)</sup>. Foreign objects enter the body creating a puncture wound and then can penetrate upto any depth. These injuries can be categorized into two groups; penetration of an immobile object or penetration of a mobile object (1,2). This impaled body may either completely embed into the body of may remain visible on examination. Regardless of type, these impaled bodies always need prompt management to remove the object, tract revision and wound management (3). Hence, such patients should receive surgical care without any undue delay in pre-operative examination which may not give any decision making findings (3).

Due to rare presentation of such cases, there are no definitive management guidelines (1,3). Careful observation and inspection of the affected part along with the surrounding environment is essential with minimal handling, and prompt transfer to an equipped emergency unit, tetanus prophylaxis, IV antibiotics and surgical removal and debridement are crucial for fruitful results (2,4). Pain, unconsciousness or poor cooperation by patients may mask the Neuro vascular deficits which may ultimately compromise the

outcomes (5). This manuscript reports a successful incident of management of impalement injury in a pediatric patient.

#### Case report

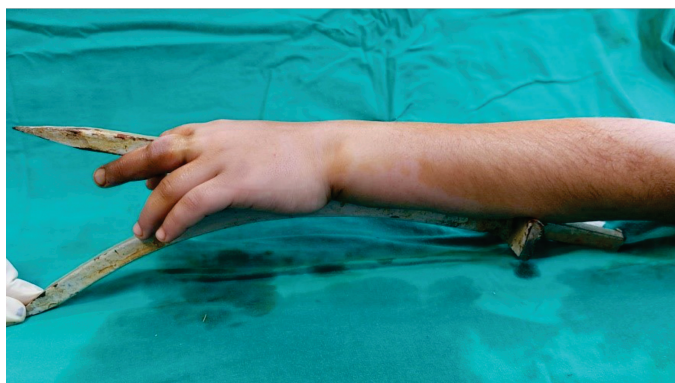A 9-year-old boy presented with a history of accidental slip while trying to catch a ball on the wall of the public playground and sustained a penetrating injury over the right hand by iron fence, the entrapped iron fence was detached from the remaining fence by cutting it and he presented within an hour of the injury (Fig 1).



**Figure 1:** Preoperative view, showing impaled spike railing (volar view).

On arrival to the emergency department, patient was managed as per the ATLS protocol; tetanus prophylaxis and broad-spectrum antibiotic were administered.

The spike railing penetrated through and through from the volar aspect of the right distal forearm and exited from the 2<sup>nd</sup> web space on the volar aspect of the palm in the region of flexor zone II. Middle finger appeared dusky and congested, along with restricted movement (fig 2)

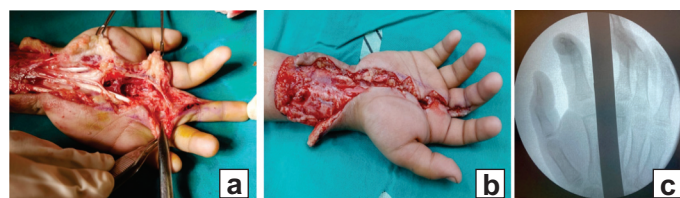


**Figure 2:** Preoperative view, showing impaled spike railing (dorsal view).

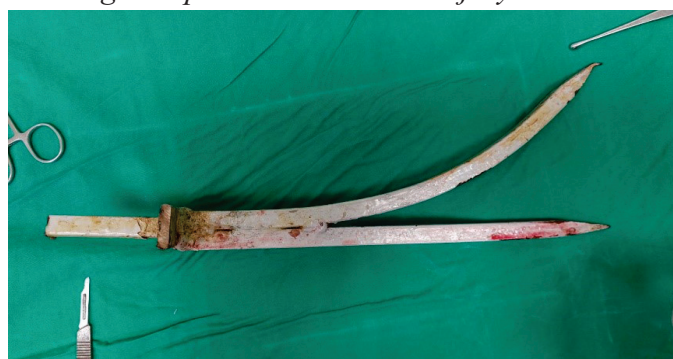**Table 1:** Showing preoperative and postoperative hand examination.

Examination	Preoperative finding	Post operative finding
Capillary Refill	Absent on middle finger	Present
Pin prick	Bright red in all digits, Middle finger appeared dusky	Bright red in all digits
Finger movements	Restricted	Restricted initially, full range on 6 months follow up

The patient was immediately taken for exploration under general anesthesia. Wound was washed, avoiding excessive movements to avoid injury to the underlying structures. The spike railing was removed by carefully extending and connecting the railing track, wound was explored and spiked iron was withdrawn under fluoroscopic image guidance (fig 3, 4) taking utmost care without injuring surrounding structures (video 1). After removing the spike rail, middle finger vascularity was restored (video 2). On exploration, luckily all the structures were found to be intact median nerve was found compressed above the rail spike, nerve appeared healthy after removal of the spike, and there was no skeletal injury (fig 3).

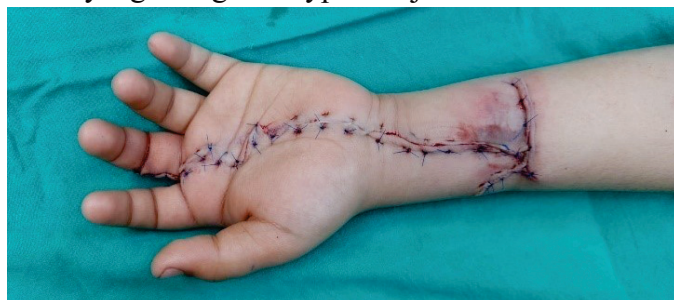

**Figure 3:** The per-operative images after removal of the rail spike, showing, **a)** intact structures including the tendons and the median nerve, **b)** Vascularity of middle finger was restored, **c)** Fluoroscopic image showing rails pike and no skeletal injury.



**Figure 4:** The railing after removal

The wound was washed thoroughly with saline. The wound was then closed with 4/0prolene suture. Postoperatively, the patient was monitored overnight for vascularity. On the 1<sup>st</sup> post operative day, the wound was healthy, middle finger was well perfused and there were decreased sensations on the radial aspect of middle finger (fig 4). Patient was discharged with follow up advised in outpatient department. Stitches were removed on the 10<sup>th</sup> post operative day and the patient was actively moving his hand. Sensations were later improved and were fully restored on 30<sup>th</sup> postoperative day. The key to success during the planning & execution of the case was sound knowledge of anatomy of hand, careful & meticulous dissection, and tissue respect. Another point of consideration is to bring awareness in the society regarding such type of injuries.



**Figure 5:** Post operative picture showing well vascularised fingers also the medial skin flap edge is poorly perfused (this healed well with dressings)

## Discussion

The distal edges of metal railing used in fences or gates may either end sharply or terminate in decorative designs<sup>(6)</sup>. In certain cases, these edges are fashioned into pointed spear-shaped ends serving as a deterrent to unauthorized entry. Literature in impalement injuries consistently advises that the penetrating objects should remain in-situ, and if necessary, shortened externally to facilitate safe transport to medical facility. This practice aims to prevent catastrophic hemorrhage that could result from prematurely removing the object, which might be tamponading a vessel or stabilizing nearby tissues.

Several case reports have documented successful management of similar injuries<sup>(7)</sup>. The treatment of such impalement injuries demands extreme caution-the removal of foreign objects should only occur in a controlled surgical setting, ideally within an operating room and under expert supervision. Prompt transfer to a tertiary care centre and coordinated surgical intervention are crucial, as these injuries often present complex challenges during prehospital care, transportation and operative management. Therefore, all healthcare facilities should maintain awareness of this rare but critical clinical scenario and its associated complications<sup>(6)</sup>.

Comprehensive trauma assessment and resuscitation should precede any focus on the local wound. Minimal handling of the foreign body, removal under direct vision in operation theatre, meticulous debridement and administration of prophylactic antibiotics to prevent infection remain the core principle of management<sup>(7)</sup>.

In the presented case, the patient fortunately sustained no major structural or vascular damage-an uncommon outcome in hand impalement injuries. They achieved complete recovery and were found to be in good health during subsequent follow up visits to the department.

## Conclusion:

Such injuries generally cause severe structural damage, but our patient presented with minimal internal damage which was treated accordingly with no residual functional loss.

**Conflict of interest:** None

**Source of funding:** None

## Author's Contribution:

**Dr. Muhammad Imran Khan:** Data Analysis, Conception and design and final approval of the study.

**Dr. Asma Sarfaraz:** critical revision, data analysis and final approval of the study

**Dr. Hassan Tahir:** Interpretation and data analysis, Data Collection, agreement to be accountable for all aspects of the work and final approval of the version to be published

**Dr. Namia cho:** Conception and design of the study, Data analysis, and final approval of the study.

## References

- 1 Singh SB, Vardhan H, Silwal K, Upadhyaya DN. The Unusual Impalement Injuries of the Hand. *Curr Health Sci J*. 2021 Jan-Mar;47(1):123-125. doi: 10.12865/CHSJ.47.01.20. Epub 2021 Mar 31. PMID: 34211759; PMCID: PMC8200602.
- 2 Ohn MH, Ohn KM. A case of impalement injury of finger. *BMJ Case Rep*. 2020 Dec 12;13(12):e239234. doi: 10.1136/bcr-2020-239234. PMID: 33310836; PMCID: PMC7735129.
- 3 Scaglia M, Negri S, Pellizzari G, Amarossi A, Pasquetto D, Samaila EM, Maluta T, Vecchini E, Ricci M, Valentini R, Magnan B. Impalement injuries of the shoulder: a case report with literature review. *Acta Biomed*. 2022 Mar 10;92(S3):e2021565. doi: 10.23750/abm.v92iS3.12563. PMID: 35604257; PMCID: PMC9437680.
- 4 Gachabayov M. Challenges of impalement injuries. *Archives of Trauma Research*. 2017 Jul 1;6(3):53-4..
- 5 Basit S, Lone AH, Khursheed O, Rashid S, Arah R. Penetrating injury of right hand due to impalement of a wooden foreign body in a professional wood cutter: a case report. *Int J Health Sci Res*. 2015;5(3):454-6.
- 6 James J. Pediatric Forearm Impalement Injury: A Case Report with Review of Literature. *J Orthop Case Rep*. 2023 Oct;13(10):71-74. doi: 10.13107/jocr.2023.v13.i10.3940. PMID: 37885653; PMCID: PMC10599385.
- 7 Rasheed T, Hill C, Khan K, Brennan M. Paediatric hand injuries caused by spiked railings. *J Hand Surg Br*. 1999 Oct;24(5):615-6. doi: 10.1054/jhsb.1999.0206. PMID: 10597946.

(Base upon Minimum Requirements for Writing and Editing of Manuscripts)

## Introduction

The new Editorial Board of Pakistan Journal of Plastic Surgery during its meeting held on January, 2019 decided to follow the “Uniform requirements for manuscripts submitted to Biomedical Journals: writing & Editing for Biomedical Publications by International Committee of Medical Journal Editors. A brief account of minimum requirements is given below for assisting the authors, reviewers and editors, the full text can be read, ([www.icmje.org](http://www.icmje.org)). Moreover plagiarism policy of ICMJE, Higher Education Commission and PMDC will be observed. It is authors' responsibility to apprise them of plagiarism in any form including paraphrasing and self plagiarism. The Plagiarism Standing Committee of Pakistan Journal of Plastic surgery would deal with cases of plagiarism and comprise of staff members, and editors. Those claiming intellectual/ idea or data theft of an article must provide documentary proof in their claim otherwise their case will be sent for disciplinary action.

## General Principles

### 1. Title Page

The title page should carry the following information:

1. The title of the article. Concise titles are easier to read than long, convoluted ones. Authors should include all information in the title that will make electronic retrieval of the article both sensitive and specific.
2. Authors' names and Title of the Program. The names and other relevant information should be on title page only to ensure blind peer review of research article.
3. The name of the department(s) and institution(s) to which the work should be attributed.
4. Disclaimers, if any.
5. Corresponding authors. The name, mailing address, telephone and fax numbers, and e-mail address of the author responsible for correspondence about the manuscript.
6. Source(s) of support in the form of grants, equipment, drugs, or all of these.
7. Word counts. A word count for the text only (excluding abstract, acknowledgments, figure legends, and references). A separate word count for the Abstract is also useful for the same reason.

8. The number of figures and tables.
9. Conflict of Interest Notification Page

### 2. Conflict of Interest Notification Page

To prevent the information on potential conflict of interest for authors from being overlooked or misplaced, it is necessary for that information to be part of the manuscript. It should therefore also be included on a separate page or pages immediately following the title page.

### 3. Abstract and Key Words

An abstract (requirements for length and structured format vary by journal) should follow the title page. The abstract should provide the context or background for the study and should state the study's purposes, basic procedures (selection of study subjects or laboratory animals, observational and analytical methods), main findings (giving specific effect sizes and their statistical significance, if possible), and principal conclusions. It should emphasize new and important aspects of the study or observations.

Authors are requested to provide, and identify as such, 3 to 10 key words or short phrases that capture the main topics of the article. These will assist indexers in cross-indexing the article and may be published with the abstract. Terms from the Medical Subject Headings (MeSH) list of Index Medicus should be used.

### 4. Introduction

Provide a context or background for the study (i.e., the nature of the problem and its significance). State the specific purpose or research objective of, or hypothesis tested by, the study or observation; the research objective is often more sharply focused when stated as a question. Both the main and secondary objectives should be made clear, and any pre-specified subgroup analyses should be described. Give only strictly pertinent references and do not include data or conclusions from the work being reported.

### 5. Material and Methods

The Methods section should include only information that was available at the time the plan or protocol for the study was written; all information obtained during the conduct of the study belongs in the Results section.

#### (a) Selection and Description of Participants

Describe your selection of the observational or

experimental participants (patients or laboratory animals, including controls) clearly, including eligibility and exclusion criteria and a description of the source population. The guiding principle should be clarity about how and why a study was done in a particular way. When authors use variables such as race or ethnicity, they should define how they measured the variables and justify their relevance.

### **(b) Technical Information**

Identify the methods, apparatus (give the manufacturer's name and address in parentheses), and procedures in sufficient detail to allow other workers to reproduce the results. Give references to established methods, including statistical methods (see below); provide references and brief descriptions for methods that have been published but are not well known; describe new or substantially modified methods, give reasons for using them, and evaluate their limitations. Identify precisely all drugs and chemicals used, including generic name(s), dose(s), and route(s) of administration. Also describe diagnostic or therapeutic procedures if part of the study design.

### **(c) Statistics**

Describe statistical methods with enough detail to enable a knowledgeable reader with access to the original data to verify the reported results. When possible, quantify findings and present them with appropriate indicators of measurement error or uncertainty (such as confidence intervals). Define statistical terms, abbreviations, and most symbols. Specify the computer software used.

## **6. Results**

Present your results in logical sequence in the text, tables, and illustrations, giving the main or most important findings first. Do not repeat in the text all the data in the tables or illustrations; emphasize or summarize only important observations.

When data are summarized in the Results section, give numeric results not only as derivatives (for example, percentages) but also as the absolute numbers from which the derivatives were calculated, and specify the statistical methods used to analyze them. Restrict tables and figures to those needed to explain the argument of the paper and to assess its support. Use graphs as an alternative to tables with many entries; do not duplicate data in graphs and tables.

## **7. Discussion**

Emphasize the new and important aspects of the study

and the conclusions that follow from them. Do not repeat in detail data or other material given in the Introduction or the Results section. For experimental studies it is useful to begin the discussion by summarizing briefly the main findings, then explore possible mechanisms or explanations for these findings, compare and contrast the results with other relevant studies, state the limitations of the study, and explore the implications of the findings for future research and for clinical practice.

Link the conclusions with the goals of the study but avoid unqualified statements and conclusions not adequately supported by the data. Avoid claiming priority and alluding to work that has not been completed. State new hypotheses when warranted.

## **8. References**

### **(a) General Considerations Related to References**

Although references to review articles can be an efficient way of guiding readers to a body of literature, review articles do not always reflect original work accurately. Small numbers of references to key original papers will often serve.

Avoid using abstracts as references. References to papers accepted but not yet published should be designated as "in press" authors should obtain written permission to cite such papers as well as verification that they have been accepted for publication. Information from manuscripts submitted but not accepted should be cited in the text as "unpublished observations" with written permission from the source.

Avoid citing a "personal communication" unless it provides essential information not available from a public source, in which case the name of the person and date of communication should be cited in parentheses in the text. For scientific articles, authors should obtain written permission and confirmation of accuracy from the source of a personal communication.

For articles published in journals indexed in MEDLINE, the Pakistan Journal of Plastic Surgery considers PubMed (<http://www.pubmed.gov>) the authoritative source for information about retractions.

### **(b) Reference Style and Format**

The Uniform Requirements style is based largely on an ANSI standard style adapted by the National Library of Medicine (NLM) for its databases. For samples of reference citation formats, authors should consult National Library of Medicine web site.

References should be numbered consecutively in the order in which they are first mentioned in the text. Identify references in text, tables, and legends by Arabic numerals in parentheses. The titles of journals should be abbreviated according to the style used in Index Medicus. Consult the list of Journals Indexed for MEDLINE, published annually as a separate publication by the National Library of Medicine.

## 9. Tables

Tables capture information concisely, and display it efficiently; they also provide information at any desired level of detail and precision. Including data in tables rather than text frequently makes it possible to reduce the length of the text.

Type or print each table with double spacing on a separate sheet of paper. Number tables consecutively in the order of their first citation in the text and supply a brief title for each. Do not use internal horizontal or vertical lines. Give each column a short or abbreviated heading. Authors should place explanatory matter in footnotes, not in the heading. Be sure that each table is cited in the text.

## 10. Illustrations (Figures)

Figures should be either professionally drawn and photo-graphed, or submitted as photographic quality digital prints. In addition to requiring a version of the figures suitable for printing, Pakistan Journal of Plastic Surgery ask authors for electronic files of figures in a format (e.g., JPEG or GIF) that will produce high quality images in the web version of the journal; authors should review the images.

For x-ray films, scans, and other diagnostic images, as well as pictures of pathology specimens or photomicrographs, send sharp, glossy, black-and-white or color photo-graphic prints, usually 127 x 173 mm (5 x 7 inches). Letters, numbers, and symbols on Figures should therefore be clear and even throughout, and of sufficient size that when reduced for publication each item will still be legible. Figures should be made as self-explanatory as possible, since many will be used directly in slide presentations. Titles and de-tailed explanations belong in the legends, however, not on the illustrations themselves.

Photomicrographs should have internal scale markers. Symbols, arrows, or letters used in photomicrographs should contrast with the background.

If photographs of people are used, either the subjects must not be identifiable or their pictures must be accompanied by written permission to use the photograph. When-ever possible permission for

publication should be obtained.

Figures should be numbered consecutively according to the order in which they have been first cited in the text.

## 11. Legends for Illustrations (Figures)

Type or print out legends for illustrations using double spacing, starting on a separate page, with Arabic numerals corresponding to the illustrations. When symbols, arrows, numbers, or letters are used to identify parts of the illustrations, identify and explain each one clearly in the legend.

## 12. Units of Measurement

Measurements of length, height, weight, and volume should be reported in metric units (meter, kilogram, or liter) or their decimal multiples.

Temperatures should be in degrees Celsius. Blood pressures should be in millimeters of mercury, unless other units are specifically required.

## 13. Abbreviations and Symbols

Use only standard abbreviations; the use of non-standard abbreviations can be extremely confusing to readers. Avoid abbreviations in the title. The full term for which

## 14. Drug Name

Generic names should be used. When proprietary brands are used in research, include the brand name and the name of the manufacturer in parentheses after first mentioning of the generic name in the Methods section.

## 15. Guidelines for Authors and Reviewers

All material submitted for publication should be sent exclusively to the Pakistan Journal of Plastic Surgery. Work that has already been reported in a published paper or is described in a paper sent or accepted elsewhere for publication, should not be submitted. Multiple or duplicate submission of the same work to other journal should be avoided as this fall into the category of publication fraud and are liable for disciplinary consequences, including reporting to Pakistan Medical & Dental Council and Higher Education Commission. A complete report following publication of a preliminary report, usually in the form of an abstract, or a paper that has been presented at a scientific meeting, if not published in full in a proceedings or similar publication, may be submitted. Press reports of meetings will not be considered as breach of this rule, but additional data or copies of tables and illustrations should not amplify such reports. In case of doubt, a copy of the published material should be included with a

manuscript for editors' consideration.

Authors can submit their articles by post or by E-mail: [pjpspakistan@gmail.com](mailto:pjpspakistan@gmail.com) to the Editor, Pakistan Journal of Plastic Surgery. Article can also be submitted by post or by hand on a Compact Disc (CD) with three hard copies. Articles submitted by E-mail are preferred mode of submission and do not require any hard copy.

All authors and co-authors must provide their contact telephone/cell numbers and E-mail addresses only on the title page of manuscript.

**A duly filled-in author's certification proforma is mandatory for publication. The duly signed ACP must be returned to the Pakistan Journal of Plastic Surgery office as soon as possible. The sequence / order of the authors on ACP once submitted shall not be changed at any stage.**

It is mandatory to provide the institutional ethical review board / committee approval for all research articles, at the time of submission of article.

The editors reserve the right to edit the accepted article to conform to the house-style of the Journal.

## 16. General archival and linguistic instructions

Authors should submit the manuscript typed in MS Word. Manuscripts should be written in English in British or American style/format (same style should be followed throughout the whole text), in past tense and third person form of address. Sentences should not start with a number or figure. Any illustrations or photographs should also be sent in duplicate. Components of manuscript should be in the following sequence: a title page (containing names of authors, their postal and Email addresses, fax and phone numbers, including mobile phone number of the corresponding author), abstract, key words, text, references, tables (each table, complete with title and footnotes) and legends for illustrations and photographs. Each component should begin on a new page. The manuscript should be typed in double spacing as a single column on A4 (8-1/2" x 11" or 21.5 cm x 28.0 cm), white bond paper with one inch (2.5 cm) margin on one side.

**Sub-headings should not be used in any section of the script except in the abstract. In survey and other studies, comments in verbatim should not be stated from a participating group. Acknowledgements are only printed for financing of a study or for acknowledging a previous linked work.**

From January 2016, all randomized trials should also provide a proof of being registered at the

## International RCT Registry.

## 17. Material for Publication

The material submitted for publication may be in the form of an Original research (Randomized controlled trial - RCT, Meta-analysis of RCT, Quasi experimental study, Case Control study, Cohort study, Observational Study with statistical support etc), a Review Article, Commentary, a Case Report, Recent Advances, New techniques, Debates, Adverse Drug Reports, Current Practices, Clinical Practice Article, Short Article, KAP (Knowledge, Attitudes, Practices) study, An Audit Report, Evidence Based Report, Short Communication or a Letter to the Editor. Ideas and Innovations can be reported as changes made by the authors to an existing technique or development of a new technique or instrument. A mere description of a technique without any practical experience or innovation will be considered as an update and not an original article. Any study ending three years prior to date of submission is judged by Editorial Board for its suitability as many changes take place over the period of time, subject to area of the study. Studies more than three years old are not entertained. In exceptional cases, if Editorial Board is of the view that data is important, an extension of one year may be granted. Pakistan Journal of Plastic Surgery also does not accept multiple studies/multiple end publications gathered/derived from a single research project or data (wholly or in part) known as 'salami slices'.

Original articles should normally report original research of relevance to clinical medicine. The original paper should be of about 2000-2500 words excluding abstract and references. It should contain a structured abstract of about 250 words. Three to 10 keywords should be given for an original article as per MeSH (Medical Subject Headings). There should be no more than three tables or illustrations. The data should be supported with 20 to 25 references, which should include local as well as international references. Most of the references should be from last five years from the date of submission.

Clinical Practice Article is a category under which all simple observational case series are entertained. The length of such article should be around 1500 - 1600 words with 15 - 20 references. The rest of the format should be that of an original article. KAP studies, Audit reports, Current Practices, Survey reports and Short Articles are also written on the format of Clinical Practice Article. Evidence based reports must have at least 10 cases and word count of 1000 - 1200 words with 10 - 12 references and not more than

2 tables or illustrations. It should contain a non-structured abstract of about 150 words. Short communications should be of about 1000 - 1200 words, having a non-structured abstract of about 150 words with two tables or illustrations and not more than 10 references. Clinical case reports must be of academic and educational value and provide relevance of the disease being reported as unusual. Brief or negative research findings may appear in this section. The word count of case report should be 800 words with a minimum of 3 key words. It should have a non-structured abstract of about 100 - 150 words (case specific) with maximum of 5 - 6 references. Not more than 2 figures shall be accepted.

Review article should consist of critical overview/analysis of some relatively narrow topic providing background and the recent development with the reference of original literature. It should incorporate author's original work on the same subject. The length of the review article should be of 2500 to 3000 words with minimum of 40 and maximum of 60 references. It should have non-structured abstract of 150 words with minimum 3 key words. An author can write a review article only if he/she has written a minimum of three original research articles and some case reports on the same topic.

Letters should normally not exceed 400 words, with not more than 5 references and be signed by all the authors-maximum 3 are allowed. Preference is given to those that take up points made in contributions published recently in the journal. Letters may be published with a response from the author of the article being discussed. Discussions beyond the initial letter and response will not be entertained for publication. Letters to the editor may be sent for peer review if they report a scientific data. Editorials are written upon invitation.

Between 3 to 10 key words should be given for all the category of manuscripts under the abstracts as per mesh [medical subject heading].

### **18. Thesis Based Article**

Thesis based article should be re-written in accordance with the journal's instructions to the author guidelines.

Article shall undergo routine editorial processing including external review based upon which final decision shall be made for publication. Such articles, if approved, shall be published under the disclosure by author that 'it is a Thesis based article'.

### **19. Ethical Considerations**

If tables, illustrations or photographs, which have already been published, are included, a letter of permission for re-publication should be obtained from author (s) as well as the editor of the journal where it was previously published. Written permission to reproduce photographs of patients, whose identity is not disguised, should be sent with the manuscript; otherwise the eyes will be blackened out. If a medicine is used, generic name should be used. The commercial name may, however, be mentioned only within brackets, only if necessary. In case of medicine or device or any material indicated in text, a declaration by author/s should be submitted that no monetary benefit has been taken from manufacturer/importer of that product by any author. In case of experimental interventions, permission from ethical committee of the hospital should be taken beforehand. Any other conflict of interest must be disclosed. All interventional studies submitted for publication should carry Institutional Ethical & Research Committee approval letter.

Ethical consideration regarding the intervention, added cost of test, and particularly the management of control in case-control comparisons of trials should be addressed: multi-centric authors' affiliation may be asked to be authenticated by provision of permission letters from ethical boards or the heads of involved institutes.

### **20. Authorship Criteria**

As stated in the Uniform Requirements, credit for authorship requires substantial contributions to (a) the conception and design or analysis and interpretation of the data, (b) the drafting of the article or critical revision for important intellectual content, critical appraisal of findings with literature search and actual write up of manuscript, (c) final approval of the version to be published. Each author must sign a statement attesting that he or she fulfills the authorship criteria of the Uniform Requirements.

The Journal discourages submission of more than one article dealing with related aspects of the same study. The journal also discourages the submission of case reports unless unreported from Pakistan. Unusual but already reported cases should, therefore, be submitted as letters to the editor.

### **21. Copyright**

The Pakistan Journal of Plastic Surgery is the owner of all copyright to any work published by the journal. Authors agree to execute copyright transfer of their

requested with respect to their contributions accepted by the journal.

Material printed in this journal being the copyright of the PAKISTAN JOURNAL OF PLASTIC SURGERY, may not be reproduced without the permission of the editors or publisher. Instructions to authors appear on the last page of each issue. Prospective authors should consult these before submitting their articles and other material for publication. The PAKISTAN JOURNAL OF PLASTIC SURGERY accepts only original material for publication with the understanding that except for abstracts, no part of the data has been published or will be submitted for publication elsewhere before

appearing in this journal. The Editorial Board makes every effort to ensure the accuracy and authenticity of material printed in the journal. However, conclusions and statements expressed are views of the authors and do not necessarily reflect the opinions of the Editorial Board of PJPS. Publishing of advertising material does not imply an endorsement by the PJPS.

## **22. Proofs**

Page proofs will be emailed, without the original manuscript, to the corresponding author for proof correction and should be returned to the editor within three days. Major alterations from the text cannot be accepted. Any alterations should be marked, preferable in red.