

## Research Article

# Efficacy of Bi-lobed Second Dorsal Metacarpal Artery Flap in Pediatric Electric Hand Burns

Imran Shahzad,<sup>1</sup> Ammad Rasul Ghumman,<sup>2</sup> Ghazala Tabassum,<sup>3</sup> Tariq,<sup>4</sup> Shumaila Rehman Dogar,<sup>5</sup> Farrukh Aslam<sup>6</sup>

<sup>1-4,6</sup>Jinnah Burn and reconstructive surgery centre, Lahore; <sup>5</sup>Department of Plastic Surgery, Mayo Hospital, Lahore

### Abstract

**Background:** Electrical injuries are considered a worldwide problem, with hand burns being most common in pediatric population. Reconstruction in this age group is quite challenging due to multiple factors like age, vessel size and noncompliance etc., Bi-lobed second dorsal metacarpal artery (SDMA) flap is a viable option for the reconstruction of electrical burns of hand in the pediatric patients with minimal effect on range of motion of donor site.

**Objective:** The purpose of this study is to evaluate the success rate and donor site range of motion after SDMA flap.

**Methodology:** A prospective observational cohort study was undertaken in all patients who underwent reconstruction with SDMA flap at institution from March 2016 to March 2018. Data was collected regarding flap success rate and active motion arcs of metacarpophalangeal joint (MCPJ) and proximal interphalangeal joints (PIPJ) of donor area and compared with the normal side. Patients were followed on outdoor basis for a period of 02 years

**Results:** Among 32 patients, survival rate of flap is 96.87 percent (n=31) with only partial loss of 3.12 percent (n=1). At mean follow up of 12 months, donor finger movements at MCPJ and PIPJ were almost similar to that on opposite side.

**Conclusion:** Second dorsal metacarpal artery flap is useful and reliable flap in complex reconstruction of burn hands in pediatric group in terms of survival and range of motion.

**Keywords** | Second dorsal metacarpal artery flap, Metacarpophalangeal joint, Hand burn, Pediatric electrical burn, Pediatric burn

**Received** | 07-01-2023: **Revised** | 20-02-2024 **Accepted** | 05-03-2024

**Corresponding Author** | Dr.Ammad Rasul Ghumman ; Jinnah Burn and Reconstructive Surgery Centre, Lahore

**Email:** ammad522@hotmail.com

### Introduction

Electrical injuries (EIs) are considered to be the worldwide problem given the widespread use in our daily life. It's of no surprise that most of these victims are small children & teenagers.<sup>1</sup> In this pediatric population, hand burns remain the most common as children mostly explore their surroundings with hands.<sup>2</sup> Etiology also differs from adult population as dorsal hand burns are mostly scald burn and volar ones are mostly due to contact and electrical burns.<sup>3</sup> Electrical injuries are

divided into low (60–1000 V, usually 220 to 360 V) and high voltage (>1000 V) injuries.<sup>4</sup> Low voltage injuries mostly are due to biting electrical cords, placing metallic objects in wall sockets and direct contact with live wires and electrical appliances.<sup>5</sup> Hand electrical burns are challenging considering their anatomy. Volar hand skin is unique due to high density of Merkel's tactile disks, Meissner's tactile corpuscles, Vater-Pacini's corpuscles and free nerve ending, causing a devastating sensory loss after burns. Also close approximation of bones, tendons and blood vessels to overlying skin making

them easily vulnerable to deep burns leading to functional disability<sup>6</sup>. As compared to adults, pediatric skin is thinner and more prone to injury. These injuries require hospitalization in specialized burn centers, and may need multiple debridement. As electric burns tend to be deep, exposure of tendons and bones are common. The reconstruction is challenging in these patients considering factors like age, vessel size, non-compliance etc.

The use of first dorsal metacarpal artery flap from index finger by Coleman and Anson reported its use to cover such defects<sup>7</sup>. Later on Earley used second dorsal metacarpal artery to raise flap from long finger<sup>8</sup>. Both traditional flaps from either fingers are usually of inadequate size (>2.4 x 4 cm) for coverage of complex defects<sup>9</sup>. Dauphin and Casoli illustrated that dorsal inter-carpal arch give rise to second dorsal metacarpal artery<sup>10</sup>. Smith and Harrison used both the first and second dorsal metacarpal arteries to raise pedicled bi-lobed flap<sup>11</sup>, but Zhang et al. modified this technique by raising flap only on second dorsal metacarpal artery (SDMA) thus avoiding sacrificing first dorsal metacarpal<sup>12</sup>. Theoretically there is decreased range of motion of metacarpophalangeal joint and proximal interphalangeal joint after flap harvesting from dorsum of 1<sup>st</sup> and 2<sup>nd</sup> digit. However, in this study no compromise of joint movement is observed. The main focus of this study is to establish success rate and the postoperative range of motion of donor areas joints after SDMA flap.

## Methodology

This is a prospective cohort observational study done in Jinnah Burn and Reconstructive Centre, Lahore from March 2016 to March 2018.

After approval from our institutional board and ethical committee, all patients were identified through our record and registry. All pediatric group patients who have exclusively hand burns due to electrical injury are included in the study as shown in figure 1. Exclusion and inclusion criteria of patients are shown in Table 1. Prior to SDMA flap, all the wounds were debrided as shown in figure 2. The flap survival rate is observed post operatively in terms of partial and complete loss. Patients were followed on outdoor basis for the period of 2 years during this period all patients received standard post-op care and physiotherapy. Range of motion is measured at 2years follow up of MCPJ and IPJ of index and middle finger of donor hand and compared with normal hand corresponding digits. The functional outcome of metacarpophalangeal and proximal inter-

phalangeal joints of index and middle finger by comparing them to normal hand shown in figure 3.

**Table 1:** Inclusion and exclusion criteria

Inclusion criteria
All hand burn due to electrical injury.
Only involving unilateral hand
Age <12 years
No associated injuries.
Exclusion criteria
Soft tissue loss other than electrical burns.
Age >12 years
Electrical burns Involving both hands
Patients with associated injuries (fractures, vascular compromise etc.)
Patients with congenital hand anomalies, vascular diseases, Diabetes.

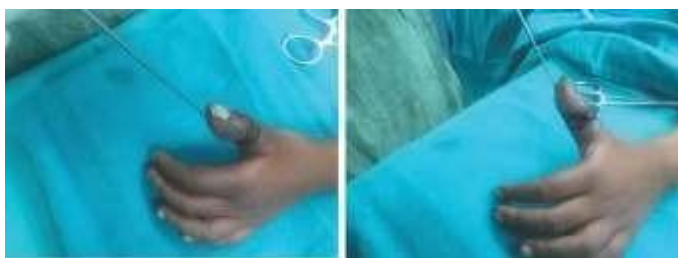## Results

Overall 32 patients (Male 24 , Female 08 ) with mean age of 09 years were accepted in this study. At the end of study, the mean dimension of flaps from index and long finger was 3.6×1.8cm (range, 3.2×1.6 cm to 4.0×2 cm) and 3.8×1.8 cm (range, 3.1 ×1.5 cm to 4.0×2 cm) respectively, with mean pedicle length of 3.4 cm (range, 2.9 cm to 3.8 cm). Survival rate was 96.78 percent (n=30) with partial loss of 3.12 percent (n=1), which healed without any intervention.

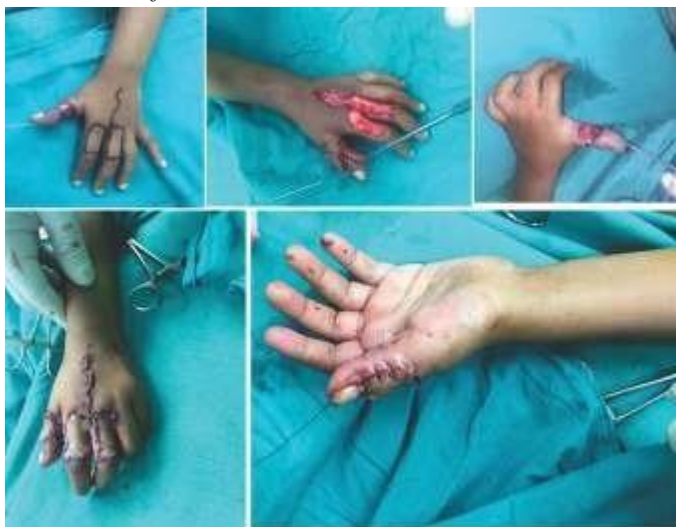At the end of follow up, the active motion arcs of metacarpophalangeal joints (MCPJ) and proximal interphalangeal joints (PIPJ) were measured and compared with contralateral uninjured hand. The average active motion arc was measured over index finger which showed value of 82 degrees (range 80 to 85 degrees) at MCPJ and 98 degrees (range, 90 to 108 degrees) at PIPJ, as compared to contralateral unaffected side where active motion was measured to be 87 degrees (range, 83 to 90 degrees) at MCPJ and 105 degrees (range, 94 to 112 degrees) at PIPJ.

Similarly, average active motion arc was measured over middle finger which showed value of 82 degrees (range, 80 to 90 degrees) at MCPJ and 99 degrees (range, 93 to 104 degrees) at PIPJ, as compared to contralateral unaffected side where mean active motion is calculated to be 86 degrees (range, 82 to 93 degrees) at MCPJ and 105 degrees (range, 98 to 110 degrees) at PIPJ.

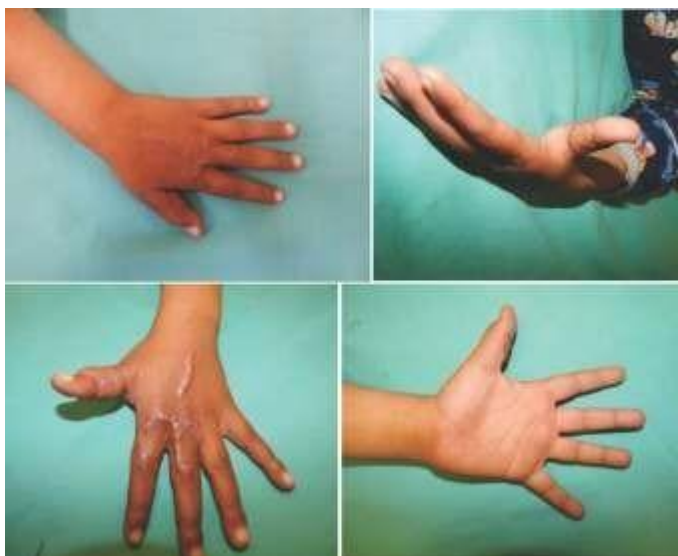The comparison of normal side with injured side of both joints of middle and index finger is represented in figure 4&5 respectively.



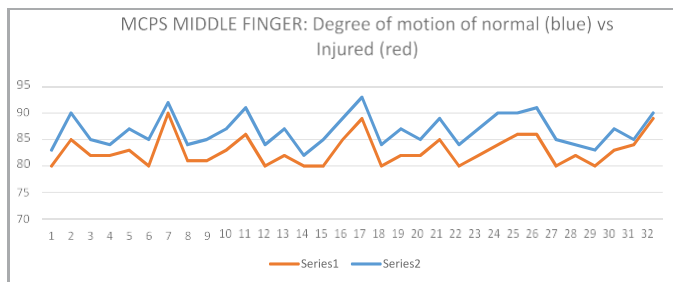
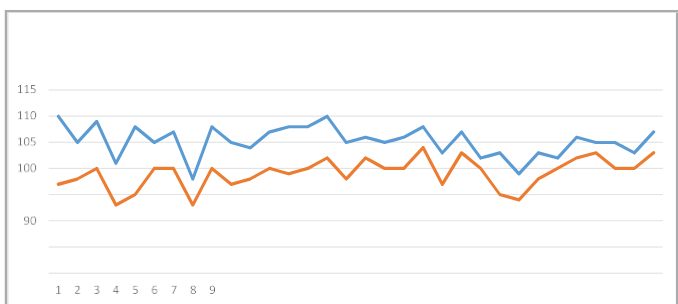
**Figure 1:** 7 year old male presented history of electrical burn over left thumb.



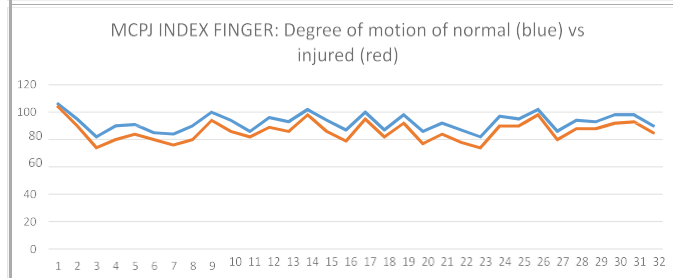
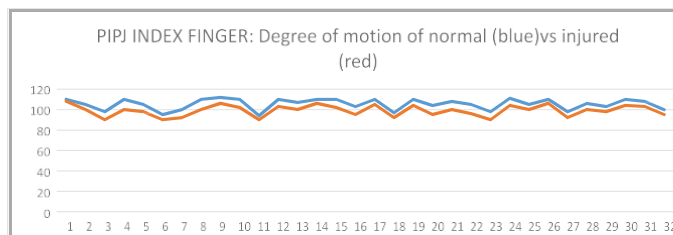
**Figure 2:** Per-operative planning and execution of SDMA flap after debridement of wound.



**Figure 3:** 1 year follow up.



**Figure 4:-** PIPJ & MCPJ of middle finger



**Figure 5:** PIPJ & MCPJ of index finger

**Discussion**

Electrical injuries usually involve deep tissues and needs multiple debrima before definitive cover. Most of the volar wounds can be treated with simple grafting but in case of such injuries it is not uncommon if bone or tendon gets exposed, such perplex wounds are often problematic and require complex reconstruction.

Amongvast majority of options for coverage, first dorsal metacarpalarteryusage is limited by its reachandsize.<sup>13,14</sup> Likewise, distant flaps like cross-abdomen flap, pedicle groin flaps are two staged procedures associated with high infection rate.<sup>15,16</sup> Other alternatives like reverse dorsal metacarpal artery flap or reverse radial artery perforator flap may solve the problem but are associated with risk of vascular compromise due to their reverse blood supply.<sup>17,18</sup> Last but not least, free flap or free venous flaps may solve the problem, but such procedures require specialized centres, microvascular anastomosis and carries significant risk of anastomosis failure.<sup>19,20,21</sup>

The bi lobed second dorsal metacarpal flap is an ideal option for combined defects requiring sensate coverage with additional benefit of long pedicle with sufficient reach without any tension.<sup>22</sup> The only complication we encountered was the distal end necrosis in one flap,

which is not uncommon, and it healed with secondary intention.<sup>23</sup>

The contraindications include damage to donor area of the metacarpal artery and a defects which are small enough to be covered by other local flaps.

This technique provides many advantages including a single stage, vast reach, minimal donor site morbidity, and adequate flap size. The disadvantages include minimal sensory loss at donor site and tedious dissection.

### Conclusion

The bi-lobed second dorsal metacarpal artery flap is an excellent sensate option for intricate defects of hand in paediatric patients after electrical injuries with minimal donor site morbidity in terms of range of motion.

**Conflict of Interest:** *None*

**Funding Source:** *None*

### References

1. Dimick AR. Burns and electrical injuries. In: Tintinalli JE, Krome RL, Ruiz E, eds. Emergency Medicine. 3<sup>rd</sup> ed. Philadelphia, PA: McGraw-Hill Inc; 1992:691 Y694.
2. Feldmann ME, Evans J, O SJ. Early management of the burned pediatric hand. J Craniofac Surg. 2008; 19 (4):942-50.
3. Clarke HM, Wittpenn GP, McLeod AM, Candlish SE, Guernsey CJ, Weleff DK, Zuker RM. Acute management of pediatric hand burns. Hand Clin.
4. Koumbourlis AC. Electrical injuries. Crit Care Med. 2002;30:S424-30.
5. Sharma RK, Parashar A. Special considerations in paediatric burn patients. Indian J Plast Surg. 2010; 43: S43-50.
6. Kamolz LP, Kitzinger HB, Karle B, Frey M. The treatment of hand burns. Burns. 2009;35(3):327-37.
7. COLEMAN SS, ANSON BJ. Arterial patterns in the hand based upon a study of 650 specimens. Surg Gynecol Obstet. 1961;113:409-24.
8. Small JO, Brennen MD. The second dorsal metacarpal artery neurovascular island flap. Br J Plast Surg. 1990; 43(1):17-23.
9. Dauphin N, Casoli V. The dorsal metacarpal arteries: anatomical study. Feasibility of pedicled metacarpal bone flaps. J Hand Surg Eur Vol. 2011;36(9):787-94.
10. Smith PJ, Harrison SH. The "seagull" flap for syndactyly. Br J Plast Surg. 1982;35(3):390-3.
11. Zhang X, Yang L, Shao X, Wen S, Zhu H, Zhang Z. Use of a bilobed second dorsal metacarpal artery-based island flap for thumb replantation. J Hand Surg Am. 2011;36(6):998-1006.
12. Muyltermans T, Hierner R. First dorsal metacarpal artery flap for thumb reconstruction: a retrospective clinical study. Strategies Trauma Limb Reconstr. 2009; 4(1):27-33.
13. Zhang X, Shao X, Ren C, Zhang Z, Wen S, Sun J. Reconstruction of thumb pulp defects using a modified kiteflap. J Hand Surg Am. 2011 Oct;36(10):1597-603.
14. Horta R, Barbosa R, Oliveira I, Amarante JM, Marques M, Cruz Reis J, Rebelo M. Neurosensible reconstruction of the thumb in an emergency situation: review of 107 cases. Tech Hand Up Extrem Surg. 2009;13(2):85-9
15. Jokuszies A, Niederbichler AD, Hirsch N, Kahlmann D, Herold C, Vogt PM. Der gestielte Leistenlappen zur Defektdeckung an der Hand [The pedicled groin flap for defect closure of the hand]. Oper Orthop Traumatol. 2010;22(4):440-51.
16. Zhang X, Shao X, Ren C, Wen S, Zhu H, Sun J. Coverage of dorsal-ulnar hand wounds with a reverse second dorsal metacarpal artery flap. J Reconstr Microsurg. 2012;28(3):167-73.
17. Yang D, Yang JF. The radial artery pedicle perforator flap: vascular analysis and clinical implications. Plast Reconstr Surg. 2011 Mar;127(3):1392-1393.
18. Tsai TM, D'Agostino L, Fang YS, Tien H. Compound flap from the great toe and vascularized joints from the second toe for posttraumatic thumb reconstruction at the level of the proximal metacarpal bone. Microsurgery. 2009;29(3):178-83.
19. Nakazawa H, Kikuchi Y, Honda T, Isago T, Morioka K, Itoh H. Use of an arterialised venous skin flap in the replantation of an amputated thumb. Scand J Plast Reconstr Surg Hand Surg. 2004;38(3):187-91.
20. Kimura N, Saito M, Sumiya Y, Itoh N. Reconstruction of hand skin defects by microdissected minianterolateral thigh perforator flaps. J Plast Reconstr Aesthet Surg. 2008;61(9):1073-7.
21. Earley MJ, Milner RH. Dorsal metacarpal flaps. Br J Plast Surg. 1987;40(4):333-41.
22. Chang SC, Chen SL, Chen TM, Chuang CJ, Cheng TY, Wang HJ. Sensate first dorsal metacarpal artery flap for resurfacing extensive pulp defects of the thumb. Ann Plast Surg. 2004;53(5):449-54.