

## Nevus Comedonicus: A Rare Skin Lesion

Dr. Zain-ul-Abidin, Dr. Muhammad Sheraz Raza, Dr. Moazzam Nazeer Tarar

---

### ABSTRACT

We present a case of 26 yr old male having blackish pigmented lesion with multiple sinus discharge over left side of abdomen, the lesion consisted of multiple, comedo like openings with dark keratin plugs dispersed over hypopigmented area. It was diagnosed as a nevus comedonicus on clinical and histopathological grounds. We managed him with excision of the lesion and covered with split thickness skin graft. Patient recovered completely and healthy with regular follow up from last one month.

*Key words:* Hypopigmented . Comedo. Split thickness skin graft .

### Introduction

Nevus comedonicus (NC) is a benign hamartoma of the pilosebaceous unit and is considered a rare subtype of epidermal nevus<sup>1</sup>. Nevus comedonicus (NC) or comedo nevus refers to closely arranged, grouped, often linear, slightly elevated papules that have at their center keratin plugs resembling comedones. It can be present at birth, but may occur at any time, up through middle age<sup>2</sup>. The commonest site is the face, followed by the neck, trunk and upper arm<sup>7</sup>. This disease was first described in 1895 by Kofmann who suggested the term "Comedo Nevus"<sup>3</sup>. The incidence of NC is estimated at 1/45,000, with no sex-related differences<sup>4</sup>. When NC is associated with cataracts, skeletal defects, or central nervous system abnormalities, it is called Nevus Comedonicus Syndrome (NCS)<sup>5</sup>. A diagnosis of Nevus Comedonicus may be made using a clinical examination, dermoscopy (examination of the skin using magnifying lens), and a tissue biopsy<sup>6</sup>. The case has been presented for its sheer rarity in Pakistan.

**Dr. Zain-ul-Abidin,  
Dr. Muhammad Sheraz Raza,  
Dr. Moazzam Nazeer Tarar**

*Jinnah Burn and Reconstructive Surgery Centre, Lahore.*

### Case Report

We report a case of nevus comedonicus in 26 year male patient over abdomen. There was a black pigmented lesion appeared on left side of abdomen when the patient was 10 yr old since then it has increased in parallel to body growth. It was closely arranged, dilated follicular openings with keratinous plugs resembling classic comedones (Figure 1).

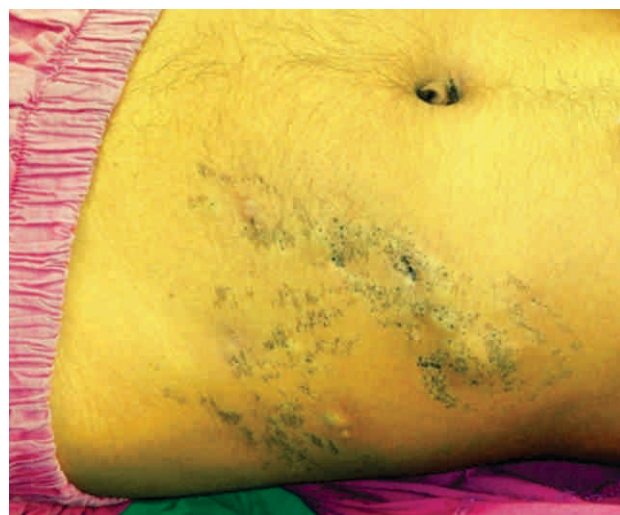


Figure 1 .  
lesion left side of abdomen, showing multiple group of pilosebaceous gland with keratin plug.

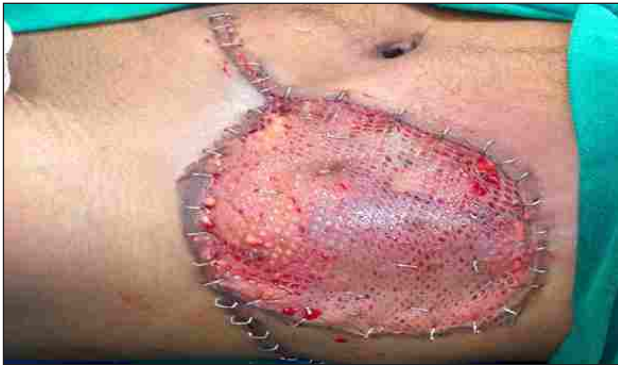

Figure 2.  
Intraoperative picture showing split thickness skin grafting done after excision of lesion.

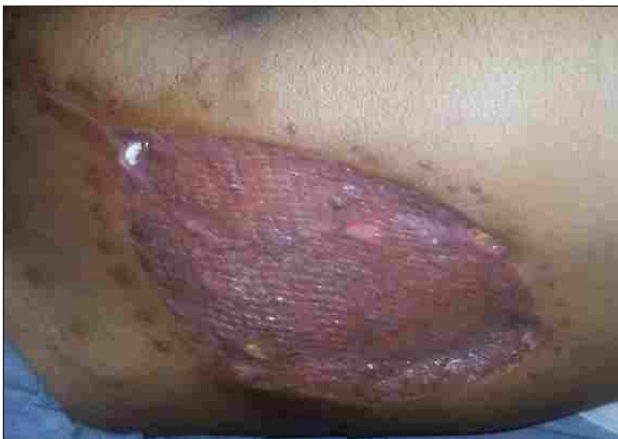

Figure 3.  
post operative wound showing graft take, on followup after 2 weeks.

There was history of multiple sinus discharge from last two years. He had taken oral and topical antibiotic creams applied multiple times but couldn't get relief. He had also taken a nine month course of anti tuberculous drugs advised by some local doctor. There was no associated skeletal and neurological abnormality. He denies any history of trauma or irritation. He was non smoker with negative family history.

Examination revealed multiple groups of dilated pilosebaceous orifices filled with black keratin plugs arranged linearly along the left side of umbilical area over abdomen. These plugs couldn't be extracted manually. Initially it was asymptomatic, but later on

there were multiple comedones, closely arranged sinus with minimal discharge were present. Face, head and neck region, extremities, including hands, feet and nails, as well as mucous membranes were spared. Family history and routine laboratory studies were unremarkable. Histopathological finding were suggestive of nevus comedonicus (Figure 4).

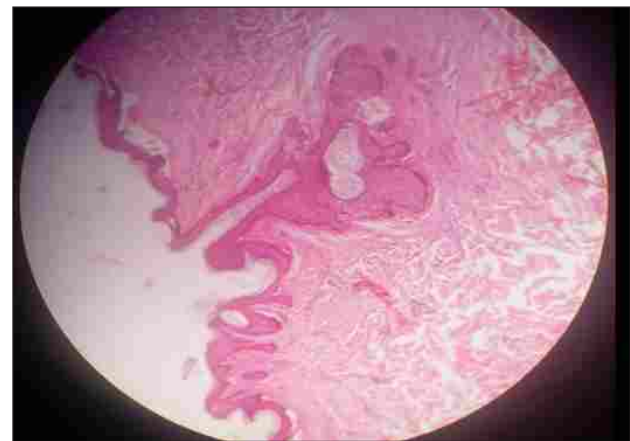

Figure 4.  
Histological section revealed, Invaginated papillary projections filled with laminated keratin plugs.

### Discussion

Naevus comedonicus is a rare hamartoma of the pilosebaceous unit.<sup>8</sup> Study of Levenson JL suggest that NEK9 mutations in NC disrupt normal follicular differentiation and identify NEK9 as a potential regulator of follicular homeostasis<sup>10</sup>. NC is classified into two main types based on its clinical characteristics<sup>3</sup>. The first type is non-pyogenic NC with acne like characteristics. The second type is NC with cysts, papules, pustules, or abscesses that undergo morphological changes<sup>11</sup>. In our patient, there were two groups of comedo like pores arranged linearly with intervening normal skin. The intervening epidermis may appear normal, hyperkeratotic, or slightly hypo- or hyperpigmented. In the inflammatory variant, there will be suppurative cysts and acne like lesions<sup>9,8</sup>.

Nevus comedonicus syndrome is the association of nevus comedonicus with non-cutaneous findings such as skeletal defects, cerebral abnormalities, and cataracts 8. Detailed examination of our patient did not reveal any other abnormalities.

Treatment of comedo naevus includes surgical excision with tissue expansion which is more effective in the long term than superficial shaving or dermabrasion. Topical retinoic acid and 12% ammonium lactate may be used.

NC poses a great challenge to clinicians, and the only effective treatment method is surgery. It is important for those with NC to maintain good hygiene, and antibiotics can also be used as a conservative method of treatment. As a localized treatment, retinoic acid can be used to induce the expansion and differentiation of keratinocytes, which would be effective for the elution of nevus.

In addition, ammonium lactate lotion softens the epidermis, thereby promoting the excretion of nevus. Other available treatments include the mechanical removal of nevus, dermabrasion or laser therapy. However, these methods cannot prevent recurrence of the lesion and surgical removal is the treatment of choice for NC. Cases with larger affected areas require staged excision or skin grafting. In some cases, reconstruction using a tissue expander would be helpful 11.

In conclusion, we are presenting a case of linear nevus comedonicus on abdomen. This rare case has been presented for its classical presentation and rarity in Pakistan. Previously a case of epidermal nevus syndrome has been reported in Pak peads journal 12.

#### References :

1. Zarkik S, Bouhllab J, Methqal A, Afifi Y, Senouci K, Hassam B. Keratoacathoma arising in nevus comedonicus. *Dermatol Online J*. 2012 Jul 15;18(7):4
2. Yadav P, Mendiratta V, Rana S, Chander R. Nevus Comedonicus Syndrome. *Indian J Dermatol*. 2015 Jul-Aug;60(4):421
3. Kofmann S. Ein Fall Von Selfener Localisation and Verbreitung Von Komedonen Arch Derm Syph 1895;32:177178.
4. Marcus J, Esterly NB, Bauer BS. Tissue expansion in a patient with extensive nevus comedonicus. *Ann Plast Surg*. 1992;29:362–366
5. Qian G, Liu T, Zhou C, Zhang Y. Naevus Nevus comedonicus syndrome complicated by hidradenitis suppurativa-like lesions responding to acitretin treatment. *Acta Derm Venereol*. 2015 Nov;95(8):992-3.
6. Kaminska- Winciorek G, Spiewak R. Dermoscopy on nevus comedonicus: a case report and review of the literature. *Postepy Dermatol Alergol*. 2013 Aug;30(4):252-4.
7. Kikkeri NN, Priyanka R, Parshawanath H. Nevus comedonicus on scalp: a rare site. *Indian J Dermatol*. 2015 Jan-Feb;60(1):105.
8. Thomas VD, Swanson NA, Lee KK. Benign epithelial tumors, hamartomas and hyperplasias. In: Wolff K, Goldsmith LA, Katz SI, Gilchrist BA, Paller AS, Leffel DJ, editors. *Fitzpatrick's Dermatology in General Medicine*. New York: McGraw Hill; 2008. pp. 1059–60
9. Moss C, Shahidullah H. Naevi and other developmental defects. In: Burns T, Breathnach S, Cox N, Griffiths C, editors. *Rook's Textbook of Dermatology*. Oxford: Wiley-Blackwell; 2010. pp. 18.11–12

10. Levinsohn JL, Sugarman JL; Somatic Mutations in NEK9 Cause Nevus Comedonicus. Yale Center for Mendelian Genomics, McNiff JM, Antaya RJ, Choate KA. Am J Hum Genet. 2016 May 5;98(5):1030-7.
11. Jeong HS, Lee HK, Lee SH, Kim HS, Yi SY. Reply: multiple large cysts arising from nevus comedonicus. Arch Plast Surg. 2012 May;39(3):261.
12. Muhammad Saeed, Akbar Malik, Nazir Malik. Epedermal nevus syndrome. Pak Paed J Dec 2009;33(4):250-2. The Children's Hospital and The institute of Child Health, Lahore

