

Transpalpebral Periosteal Sutures for Unilateral and Bilateral Browpexy

Umar Daraz Khan, Muhammad Riaz

Abstract:

Objective: Brow lift is a commonly performed procedure for forehead rejuvenation. Various techniques are described to achieve the intended results and are broadly divided into open and closed (endoscopic) methods. Open techniques involves browpexy using transpalpebral, pretrichial, coronal or temporal approaches. Our experience of Browpexy through Upper Lid using periosteal suture is described.

Methods: A total of 26 patients (18 females, 8 males) had the procedure. The average age of the patient was 46 years (range 32-63). Of these, 10 patients had unilateral and 16 had bilateral browpexy. Simple suturing was performed using absorbable 3-0 Vicryl sutures. No glabellar muscle complex manipulation was performed.

Results: With an average follow up for at least 2 years, there was a recurrence of ptosis in a unilateral browpexy, requiring non-surgical treatment using Botulinum Toxin type A.

Conclusion: Transpalpebral browpexy using periosteal sutures is a simple, useful and reproducible procedure that can be performed for both unilateral and bilateral brow ptosis. The results are comparable with little downtime and comorbidity.

Key Words: Brow Pexy, Forehead lift, Facial Rejuvenation, Upper Blepharoplasty, Brow Lift, Transpalpebral Browpexy.

Introduction.

Rejuvenation and aesthetic appearance of face, especially upper face has been challenging for Surgeons for over a century. It is not surprising that one of the leading article on upper face or forehead rhytids was published nearly a century ago.¹ The article described direct elliptical excisions of forehead and crows feet rhytids. Since the publications of

the article by Possot, improvements and refinements in approach and technique for forehead or browlift have continued to this very day. The commonly used incision are coronal that dates back to 1926,² pre-hairline incision³, small multiple incisions for endoscopic browlift⁴, limited incisions forehead lift⁵. All of the above procedures are time consuming, requiring special instrumentation and carry reasonable surgical morbidity, including sensory nerve damage, alopecia, scar stretching etc.

Transpalpebral brow lift or transblepharoplasty brow suspension⁶ concept was introduced to reduce the complications associated with the distantly located incisions for brow lift. The procedure is effective, carries less surgical morbidity and is carried out when dealing the excess skin of the upper lid at the same time and through the same

Mr. Umar Daraz Khan
MBBS, FRCS

Mr. Muhammad Riaz
FRCS (PLAST)
Corresponding Author

Umar Daraz Khan
Reshape House 2-4 High Street West Malling ME19
6QR Kent. UK
Fax and Phone. 0044 1732- 846838
E-mail: mrumarkhan@aol.com
www. re-shape.co.u

upper lid incision. The procedure also allows surgical manipulation, if necessary, of the medial eyebrow depressors including, corrugator, procerus and depressor supercillii. The procedure itself involved local soft tissue and periosteal flap design for the suspension, lifting and maintenance of ptotic brows. Various approaches and refinements have been published since then to further the scope of this access and approach.⁷⁻¹⁰ Our modification of the technique for browpexy using transpalpebral periosteal sutures is simple, effective and with least surgical morbidity.

Material and Methods

A total of 26 patients (18 females, 8 males) had the procedure done. Average age of the patient was 46 (range, 32-63). Of these 10 patients had unilateral and 16 had bilateral transpalpebral browpexy. Simple suturing was performed using absorbable 3-0 Vicryl sutures. No glabellar muscle complex manipulation was performed in the series.

Technique

Patients are examined preoperatively. Position of the lower border of the eyebrow and its relationship with the free margin of the upper orbital rim is ascertained. Patients presenting with browptosis, the lower border of eyebrow is lower than its normally acceptable position at the orbital rim often resulting in upper eyelid blepharochalasis. Brow is lifted manually to its intended or normal position. The process allows delineating the true upper eyelid skin excess and allows for the marking of the upper eye lid skin excision. In patient where unilateral browpexy is required for brow level asymmetry alone or in patients who presents with no upper lid skin excess, no upper lid skin excision is required.

Patients are operated under general anesthesia and in supine position. Marked

area on the upper eyelid and lateral half of the eyebrow is infiltrated with 1% xylocaine with adrenaline 1:200,000. In patients who present with excess skin, necessary skin and orbicularis muscle is excised. Similarly when excess preseptal or medial compartment fat is present, it can be removed at the same time. Patient without skin excess or in unilateral browpexy for brow level asymmetry correction, a curved incision is made along the lid tarsal fold. Through the upper lid skin incision, fine blunt tipped scissors are introduced to create a pocket deep to orbicularis-oculi muscle. With the skin-muscle flap elevated using a retractor, dissection is continued over the orbital free margin in a subgaleal plane up to middle of the forehead. Necessary haemostasis is achieved and with a good retraction and under direct vision, two 3-0 Vicryl sutures are placed between the under surface of the eyebrow and periosteum of the frontal bone. These two sutures are placed at the junction of the middle and lateral third and the middle of the lateral third of the undersurface of the eye brow, about 15 and 10 degree respectively, when measured from the medial free margin of each eye brow.

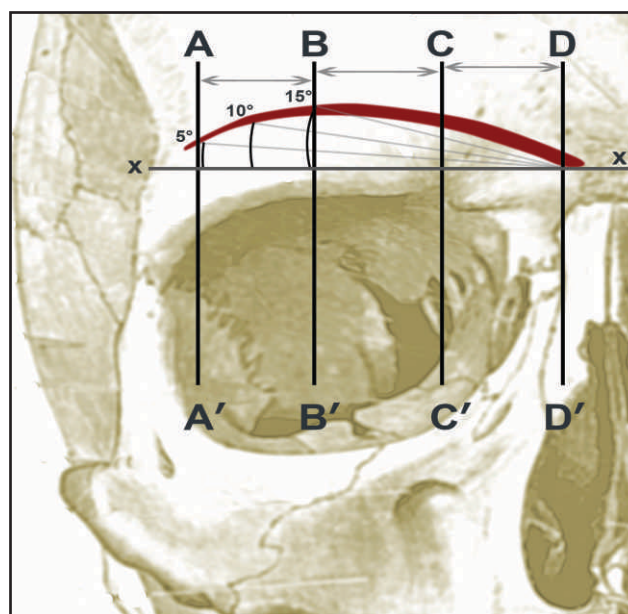


Fig. 1.

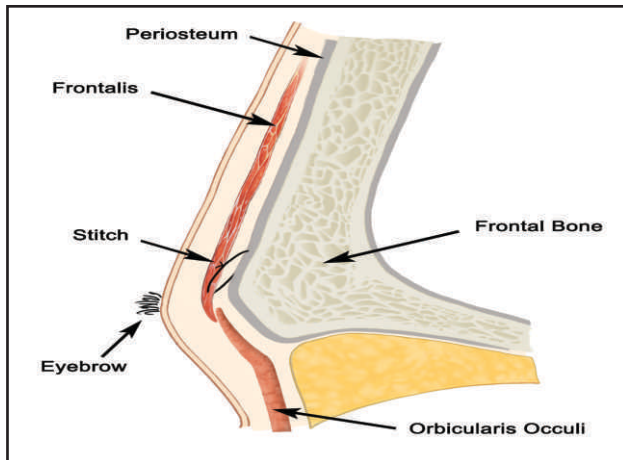


Fig. 2. (a)

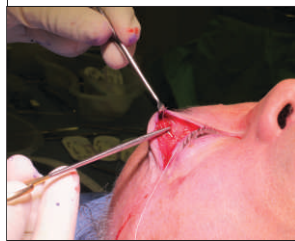

Fig. 2. (b)

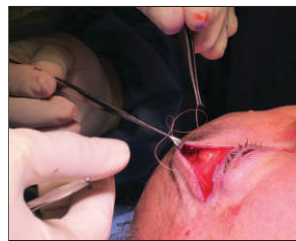

Fig. 2. (c)

Fig. 1, 2 (a-c) Before tying, adequacy of the bite and position of the suture is confirmed by a gentle pull

Once the sutures are placed, eyelid skin muscle closure is performed using continuous 5-0 nonabsorbable sutures. All patients are given a single intravenous cephalosporin and are treated as day cases.

Results

Patients were followed for at least 2 years. There was one recurrence of brow ptosis in a unilateral browpexy, the patient required non-surgical treatment using Botulinum Toxin type A.

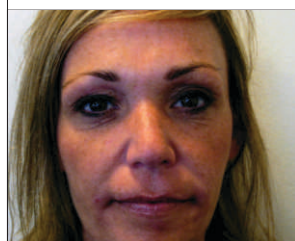


Fig. 3. (a)

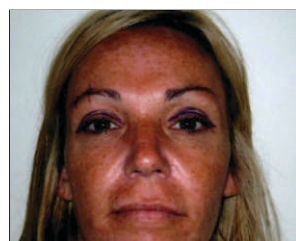

Fig. 3. (b)

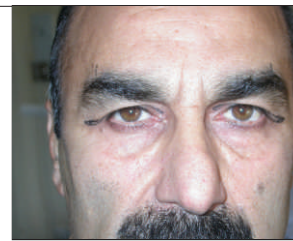

Fig. 4. (a)

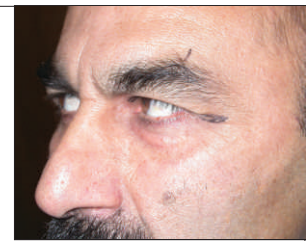

Fig. 4. (b)

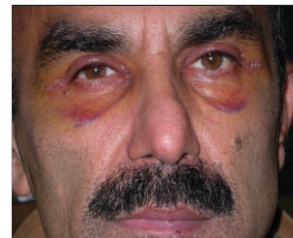


Fig. 4. (c)

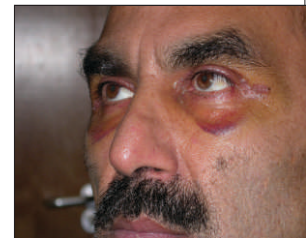

Fig. 4. (d)



Fig. 5. (a)



Fig. 5. (b)



Fig. 5. (c)



Fig. 5. (d)



Fig. 5. (e)

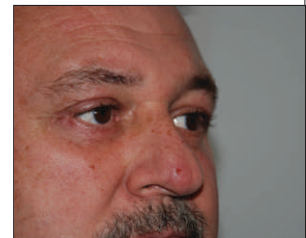

Fig. 5. (f)

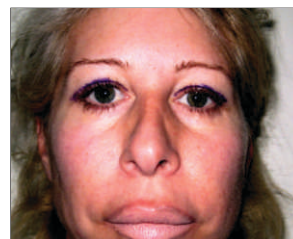

Fig. 6. (a)

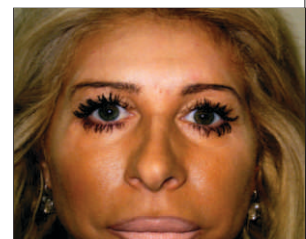

Fig. 6. (b)

Discussion

Ageing of the face is a normal process and facial rejuvenation forms a considerable part of the practice of a Plastic Surgeon. The presence of upper facial creases are not age dependent and is a manifest of the net interaction of depressors and elevators of the forehead muscles. Paired Frontalis muscles are the only elevators counteracted by medial and lateral part of Orbicularis Occuli, Corrugator Supercili, Procerus and Depressor Supercilii. The knowledge of the anatomy of this area is essential and in patients, especially younger subjects, who present with forehead and frown lines alone and without brow ptosis, can be effectively treated using Botulinum Toxin Type A therapy.¹¹ These forehead lines also constitute part of the ageing process and are commonly associated with Brow ptosis. Brow ptosis, when present, has a knock on effect on the periorbital aesthetics of the face resulting in heavy upper eyelids. The periorbital aesthetic appearance gets further compromised when there is an associated skin excess of the upper eye lid. When present, the combination of blepharochalasis with brow ptosis, constitute a combination of aesthetic as well functional compromise, resulting in visual field restriction, heavy eyelids, tired looks and headaches. Brow ptosis, when present, is typically associated with an exaggerated decent of the lateral component of the eye brow when compared to its medial component resulting in loss of the normal upward slanting arc in females (Fig 4,5) Despite the differential and normal gender dimorphism, eyebrows in both sexes are located at or above the upper orbital rim. The compensatory phenomenon is to elevate the frontalis muscle and clear the upper lid skin that further accentuates the forehead creases. Restoration of normal anatomy and aesthetic rejuvenation may require surgical relocation of the eyebrow, removal of the upper eyelid

excess skin and manipulation of the depressors of the eye brow depending on presentation. Relocation of brows requires knowledge of gender dimorphism as well various anatomical aesthetic parameters present in various ethnic groups.¹²⁻¹⁴ Plastic Surgeons and cosmetologists, are of the same opinion that the medial brow at the orbital rim with a lateral upward slant is the most acceptable aesthetic orientation of an eye brow in female.¹⁴ (Fig 1,3) Articles on techniques rejuvenating forehead and correcting brow ptosis have been frequently appearing in the literature emphasizing the details of the procedure without much attention to the results. Often the basic and acceptable aesthetic parameters are completely reversed resulting in less than acceptable outcome with medial upward slant.¹⁴ Even though there are photogrammetric analysis of eyebrow and upper eye lid measurements, including middle of the upper eyelid and lower margin of the eyebrow, are done using highly standardised photographs,¹² there is a lack of objective assessment of preoperative and postoperative measurements in the articles published so far. For similar practical reasons, highly standardise photography for eye brow and upper eyelid measurements was not carried out in the current series. However, using routine preoperative and postoperative pictures, an elevation of 2-3 mm of eyebrow was observed in most of the patients, when height between the middle of the upper eyelid to lower margin of eyebrow were measured. Authors considers an aesthetic eyebrow in female where its medial end lies at the orbital rim with an upward slant. With the eyebrow divided in equal thirds, the apex of the slant in a female should ideally lie at the junction of middle and lateral third at an angle of 15 degrees when measured from the medial end

of the eye brow. From this point the eye brow should ideally curve down lying at an angle of 10 degree in the middle of the lateral third and ending at the lateral margin lying at about 5 degree from the medial end of the eye brow. (Fig 1,3) A large national survey in America revealed that alopecia resulting from endoscopic or open brow lift was not much different and surprisingly more patients had permanent sensory loss of the scalp and forehead following endoscopic brow and forehead lift.¹⁵ The current documented brow lift procedures, open or endoscopic, do not achieve consistent, reliable or reproducible results.¹⁴ Endoscopic lift has limited value and ineffective in majority of the patients.¹⁶ The brow ptosis with or without associated blepharochalasis, is essentially correction of the reversal of the slant, that is, conversion of medial up slant back to normal lateral up slant. The drop of the lateral angle is due to the weaker lateral margin of the frontalis and not due to the powerful depressors as seen in the glabellar muscle complex medially.¹⁷ (Fig 4,5) Considering the documented lack of achievement of aesthetic goals in restoring eyebrow position while correcting brow ptosis and with almost similar distribution of alopecia, permanent sensory loss and other surgical morbidity in open or closed brow lift, transpalpebral browpexy offers a useful and efficient mechanism and technique for the correction of brow ptosis and restoration of brow position.⁷⁻¹⁰ The current approach for correcting brow ptosis is an addition to the currently available transpalpebral techniques and the simplicity of the procedure, instrumentation and time taken to perform makes it a reasonable option and surgical choice for patients and Surgeons alike. (Fig 3-6).

Conclusion

Transpalpebral browpexy using periosteal sutures is a simple, useful and reproducible procedure that can be performed for both unilateral and bilateral brow ptosis. The results are comparable and with less downtime and low morbidity.

Conflict of Interest.

None of the authors have a conflict of interest to disclose.

References:

1. Possot R. La chirurgie esthetique des rides du visage. Presse Med.27:258,1919.
2. Hunt H.I Plastic Surgery of the Head, Face, and Neck, Philadelphia: Lea and Febiger, 1926.
3. Vinas J.C. Plan general de la ritidoplastia y zona tabu. In Transaction of the 4th Brazilian Congress on Plastic Surgery, Porto Alegre, October 5-8, 1965. p.52.
4. Vasconez, L.O. The use of the endoscope in browlifting. A video presentation at the Annual Meeting of the American Society of Plastic and Reconstructive Surgeons. Washington, D.C., 1992.
5. Knize M.D., Limited-incision forehead lift for eye brow elevation to enhance upper blepharoplasty. Plast Reconstr. Surg. 97:1334, 1996.
6. Sokol AB, Sokol TP. Transblepharoplasty brow suspension. Plast Reconstr Surg 1982;69:940-944.
7. Paul MD, Subperiosteal transblepharoplasty forehead lift. Aesthetic Plast Surg. 1996; 20:129-134.
8. Ramirez OM. Transblepharoplasty forehead lift and upper face rejuvenation. Ann Plast Surg 1996;37:577-584
9. Zarem HA, Resnick JJ, Carr RM, et al. Browpexy: lateral orbicularis muscle fixation as an adjunct to upper blepharoplasty. Plast Reconstr Surg 1997;100:1258-1261.
10. Cohen BD, Reiffel AJ, Spinelli HM. Browpexy Through the Upper Lid (BUL): A New Technique of Lifting the Brow With a Standard Blepharoplasty Incision. Aesthetic Surg J.2011;31:163-169

11. Lorene ZP, Smith S, Nestor M, Nelson D, Moradi A. Understanding the Functional Anatomy of the Frontalis and Glabellar Complex for Optimal Aesthetic Botulinum Toxin Type A Therapy. *Aesth Plast Surg* 2013;37:975-983.
12. Packiriswamy V, Kumar P, Bashour M. Photogrammetric Analysis of Eyebrow and Upper Eyelid Dimensions in South Indians and Malaysian South Indians. *Aesthetic Surgery Jour* 2013;33:975-982.
13. Computerized Photogrammetry Used to Calculate the Brow Position Index. Naif-de-Andrade NT, Hochman B, Naif-de-Andrade C.B, Ferreira LM. *Aesth Plast Surg* 2012;36:1047-1051
14. Freund RM, Nolan WB III. Correlation between brow lift outcomes and aesthetic ideals for eyebrow height and shape in females. *Plast Reconstr Surg* 1996;97:1343-1348
15. Elkwood A, Matarasso A, Rankin M, Elkwitz M, Godek C. National Plastic Surgery Survey: Brow Lifting Techniques and Complications. *Plast Reconstr Surg* 2012;108:2143
16. Chiu ES, Baker DC. Endoscopic Brow Lift: A Retrospective Review of 628 Consecutive Cases over 5 Years. *Plast Reconstr Surg* 2003;112:628-663
17. Knize DM. Limited-Incision Forehead Lift for Eyebrow Elevation to Enhance Upper Blepharoplasty. *Plast Reconstr Surg* 2001;108:564-567.

Legends.

Fig 1. Relationship of an ideal eye brow to the free margin of upper orbital rim in a female. With a lateral slant directing upward, the junction of middle and lateral third should ideally lie at an angle of 15 degree, the

middle of middle third at an approximate of 10 degree and lateral end of eyebrow ending down at 5 degree, when measured from medial free margin of the eye brow.

Fig. 2. a. Sagittal section showing anatomy and plane of dissection for placing sutures in transpalpebral browpexy.

Fig. 2. b. Intraoperative pictures showing an anterior suture bite through deep surface of the eyebrow.

Fig. 2. c. Intraoperative picture showing periosteal suture bite above the orbital rim in supraciliary ridge area.

Fig 3. a. Preoperative picture of a 37 year old female interested in quadrilateral blepharoplasty and presented with brow level asymmetry.

Fig 3. b. Patient marked preoperatively for upper blepharoplasty and right browpexy.

Fig. 3. c. One year postoperative results following quadrilateral blepharoplasty and right transpalpebral browpexy.

Fig 4. a-b. Pre operative pictures of a 48 year old male with blepharochalasis of upper lid with bilateral brow ptosis.

Fig.4. c-d Postoperative pictures taken one week following quadrilateral blepharoplasty and bilateral transpalpebral browpexy.

Fig.5. a-c. Preoperative markings in a 43 year old male before quadrilateral blepharoplasty and bilateral transpalpebral browpexy.

Fig.5. d-f. Postoperative pictures taken 4 months following quadrilateral blepharoplasty with transpalpebral browpexy.

Fig. 6. a. A 39 year old lady who was interested in quadrilateral blepharoplasty with absent lateral up slant.

Fig. 6. b. 1 year following blepharoplasty with transpalpebral browpexy. Eyebrow positioning remained stable with better brow orientation.

