

# Gastrocnemius Muscle Flap Coverage of Chronically Infected Knee Joints

Dr. Munir Alam, Mr. Brian Kneafsey

---

## ABSTRACT

Chronically infected open knee joints present difficult problem. Aggressive debridement of chronically infected soft tissue and bone, irrigation and extensor mechanism reconstruction with achillis tendon graft and definitive muscle flap closure is our preferred approach (1,3). For patients with chronic infection, extensive scarring or soft tissue defects around the knee joint, transposition of the gastrocnemius muscle should be considered, because of its constant anatomy, easy dissection, versatility and moulding features combined with an excellent immunocompetence related to the high oxygen environment (2,8,9,10,11).

Six patients with chronically infected traumatic wounds, were treated with aggressive debridement, extensor mechanism reconstruction and transposition of the gastrocnemius muscle for cover.

Follow up at two years showed active knee extension with normal gait, without recurrent infection.

---

*Key Words: gastrocnemius, chronic infection, knee joint.*

## INTRODUCTION

Traumatic disruption of the knee joint is usually accompanied by extensive soft tissue injuries as well as fractures around the knee joint. In our series of six cases of traumatic chronically infected knee joint present a complex avulsion and chronic wounds of the knee joint are challenging to both orthopaedic and plastic surgeons, and require innovative cooperation (4).

The reconstructive options may be limited and the resultant defect produced by thorough debridement and the repeated lavage of the chronically infected knee wound produce defect of varying degree, where each component of the knee joint require restoration of form and function at the defect site.

Selection of a reconstructive option is based on the feasibility and relative importance of replacing each component of the defect. The exposed knee joint is a challenging problem that has most commonly dealt with using muscle flaps. Inability to accurately predict the amount of debridement required may necessitate sequential wound debridement with subsequent wound observation and the judicious use of antibiotics according to bacterial culture and sensitivity.

The gastrocnemius muscle flap is a well recognised method to provide soft tissue cover for this region and controls infection and promotes healing by increasing vascularity to the area (1,2,7,10). It can be raised far from the damaged area and tunnelled to avoid repeated undermining (9). However, success in cases of chronically infected knee joints is difficult to accomplish and depends on various measures such as debridement and lavage should be seriously taken into account before planning reconstruction of the infected knee joint.

Six cases with chronically infected knee joint are described, where such a procedure has yielded good results. 4

**Dr. Munir Alam**

46 University Town, Millat Road, Faisalabad,  
Pakistan.

Ph: +92 321 7711360

E. Mail : [mrmuniralam@gmail.com](mailto:mrmuniralam@gmail.com)

Web: [www.muniralam.com](http://www.muniralam.com)

## MATERIAL AND METHODS:

During fourteen years period from the year 2000 to 2013, total number of six patients treated for traumatic chronically infected knee joint with gastrocnemius muscle flap. Out of six patients, one patient knee wound reconstruction performed with a lateral gastrocnemius muscle flap along with a medial knee bipediced saphenous venous flow through fasciocutaneous flap to cover the repaired quadriceps mechanism in the midline.

This study of six patients include five male and one female patient.

## RESULTS:

The chronically traumatic infected knee wounds associated with bacterial contamination or established infection invariably presents difficulty in reconstructive surgery. Historically standard random pattern flaps provided inadequate resistance to infection. With the advent of the pedicled gastrocnemius muscle flap, however, regional transposition flaps became a feasible option for chronically infected traumatic infected knee joint wounds.

## DISCUSSION

Traumatic loss of the extensor mechanism of the knee is usually due to direct injuries. This usually results in extensive devitalisation of soft tissue and contamination requiring complex wounds reconstruction. As a consequence, problem of reconstruction of the extensor mechanism and infection are frequently encountered (1).

The objective of treating open infected knee joint with loss of skin and disruption of the extensor mechanism are to ensure rapid healing and restore joint function. These can be achieved by provision of soft tissue cover, control of infection and reconstruction of the extensor mechanism once the wound heals.

One of the patient's injuries included comminuted compound fracture of the patella and damage to the medial condyle of the

femur, she developed gross infection of the knee resulted in loss of patella and all of the extensor mechanisms. In addition, further dressings and 5 debridement on frequent interval produced a 8 X 9 cm large defect in the extensor mechanisms with complete loss of patella. After repeated debridement and thorough lavage of knee joint for 3 weeks, gastrocnemius flap incorporating both bellies along with an extension of the achilles tendon was used to reconstruct the extensor mechanism and to fill the gap in quadriceps mechanism as well as to cover the knee joint (Fig 1).

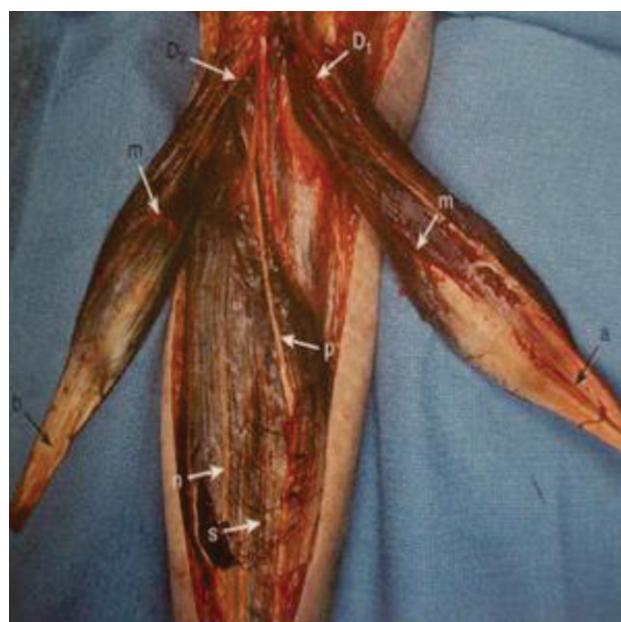

Fig 1: Medial and Lateral Gastrocnemius muscle flaps

It is well known that muscle is a vascular tissue, and the gastrocnemius muscle is especially suitable for the reconstruction of the infected knee joint, provided adequate debridement and thorough lavage is carried out before transposition of gastrocnemius muscle flap. In the lower extremity the gastrocnemius muscle is certainly the most reliable and versatile muscle to transpose (5,10,13). Gastrocnemius muscle flap is a type 1 and is divided into two parts, medial and lateral head which extends from knee joint to the heel.

Normal function of the gastrocnemius muscle is plantar flexion of the foot, either or both heads of the gastrocnemius are expandable if the solius muscle is kept intact. Each muscle head is considered as a separate unit with an approximate size 20 X 8 cm, containing separately its neurovascular bundle. The sural artery originate below the knee joint line. The estimated the location of the 6 origin of the sural artery from the popliteal artery to lie within 1 to 55 mm above the distal femur line. Other recent studies have suggested that the branches of the sural artery arise 2 to 4 cm above the knee joint line (13). It remains an easy flap to raise in a normal leg. Tissue planes are relatively clear, and the flap can be raised well outside of the zone of injury. (Fig 1, 2). With proximal arc of rotation of gastrocnemius muscle, transposition of the muscle head provide coverage of the defects of lower half thigh, knee, and upper third of the tibia (13) (Fig 3). Preoperative selection and planning of the flap does not usually require lower limb angiogram unless there is extensive crushing or penetrating traumatic injuries resulting in absent pulses, documented atherosclerotic peripheral vascular disease, or previous surgery that may have affected the vasculature of the planned flap (14). Complications related to this procedure are infrequent and are in most instances due to errors of the surgical technique (8) and recurrent infections, which is usually related to inadequate debridement of the infected and ischaemic tissue or incomplete obliteration of dead space (5).

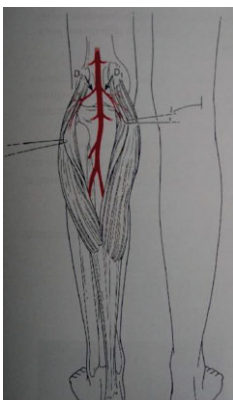


Fig 2: Pedicle – medial and lateral sural artery arising from the popliteal artery

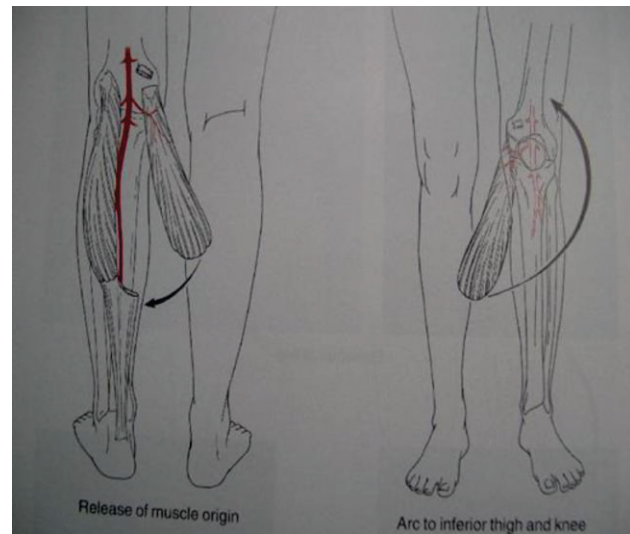


Fig 3 a: Arc of Rotation

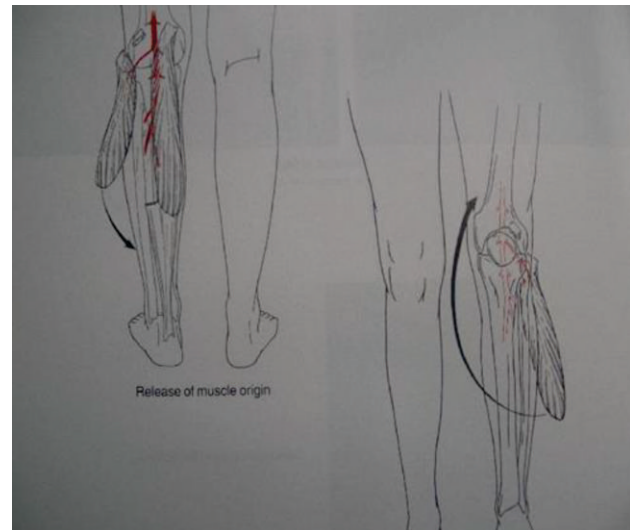


Fig 3 b: Arc of Rotation

In another patient with oval defect in extensor mechanism, the muscle was not bulky and hence it was comfortably positioned by relating it to lie obliquely across the defect. The advantages of using this procedure are that the continuity of origin with muscle which result in faster healing in a previously infected joint, and the muscle flap appears to provide the cellular, non-cellular and the oxygen environment necessary to deal with the site of infection (5,6). The problem of adhesions is minimised as the presenting surface is smooth and is covered by loose areolar tissue.



The mild extensor lag and slight limited flexion was probably due to adhesion formation in a chronically infected knee joint. Stark in 1946 reported that, “ The pedicled muscle flap is useful in the surgical treatment of chronic osteomyelitis in 84% of wounds treated with muscle flap coverage in conjunction with thorough bone debridement and antibiotic therapy as compared with 43% of patients treated without a muscle flap (15). Ger in 1977 reported the successful use of the muscle transposition flap for treatment and prevention of chronic posttraumatic osteomyelitis of the tibia (16).

### CONCLUSION

Traumatic chronically infected knee joint is a challenge for reconstructive surgeon, however, strict adherence to the basic principles of surgery, thorough debridement and lavage of infected and devitalised tissue, providing coverage of the defect with healthy vascularised muscle resulting in eliminating of chronic infection and near normal function of the knee joint.

### REFERENCES

1. Leung K. S, Kevin M, Shen H. Y, (1994) Reconstruction of Extensor Mechanism after Trauma and infection by Transposition of the Achilles Tendon: Report of Technique and Four Cases, *Journal of Orthopaedic Trauma*, Vol. 8. No. 1, pp 40-44.
2. Philip G. A, and Mixter R. C, (1983) Making the most of the Gastrocnemius Muscles, *Plast & Reconstr Surgery*, Vol. 72, pp 38-48.
3. Babu N. V et al, (1994) Reconstruction of the quadriceps apparatus following open injuries to the knee joint using pedicled gastrocnemius musculotendinous unit as bridge graft, *British Journal of Plastic Surgery*, vol 47, pp, 190-193.
4. Asko-Saljavaara S, Haajanen J, (1982) The Exposed knee joint, *The journal of Trauma*, vol. 22, 1021-1025.
5. Feldman J. J, Cohen B. E, (1978) The medial gastrocnemius myocutaneous flap: *Plast & Reconstr Surg*, pp 531-539.
6. Tellier M. A and Kon M, (1991 ) Gastrocnemius muscle transposition for bony and soft-tissue defects: *The Netherlands Journal of Surgery*, 43-1. pp 10-13.
7. Pico R, Luscher N. J, Rometsch M, De Roche R, (1991) Why the denervated Gastrocnemius Muscle Flap should be encouraged, *Annals of Plastic Surgery*, Vol 26 No 4, pp 312-324.
8. Whitney T. M, Heckler F. R, White M. J, (1995) Gastrocnemius Muscle Transposition to the femur: How high can you go? *Annals of Plastic Surgery*, vol. 34, pp 415-419.
9. Dibbell D. G, Edstrom L. E, (1980) The gastrocnemius myocutaneous flap: *Clinics in Plastic Surgery*, vol. 7, pp 45-50.
10. Casanova D et al, (2001) Management of Wounds of Exposed or Infected Knee Prosthesis, *Scand J Plast Reconstr Hand Surg* 35: pp 71-77.
11. Hersh C. K, Schenck R. C, and Williams R. P, (1995) The Versatility of the Gastrocnemius Muscle Flap, *the American Journal of orthopaedics*, pp. 218-222.
12. Isenberg J S, McPherson E, Costigan et al, (1999) Salvage and Reconstruction of Complex Post-Operative Knee Wounds: A successful surgical protocol, *Journal of Reconstructive Microsurgery*, Vol 15, No 2: pp 115-118.
13. M Alam, C Lawlor, M O'Donnell, (2007) Versatility of gastrocnemius muscle flap, How high can you reach? *Plast & Reconstr Surgery*, Vol 120(7): pp 2129-2130,

14. Miguel A. Mendez-Fernandez, (1998) Failure of a Gastrocnemius Muscle Flap Due to an Isolated High-Grade Stenosis of the Sural Artery, *Annals of Plast Surgery* Vol 40, No 2: pp 186-188.
15. Stark W. J. (1946) The use of pedicled muscle flaps in the surgical treatment of chronic osteomyelitis resulting from compound fractures, *J Bone Joint Surg Am*, Vol 28 (2): 343 -350 .
16. Ger R. (1977) Muscle transposition for treatment and prevention of chronic post-traumatic osteomyelitis of the tibia, *J Bone Joint Surg Am*, [jbjs.org](http://jbjs.org)

