

# The Use of A Random Pattern Fasciocutaneous Flap for Coverage of Exposed Bone on The Hind Limb of A Rothschild's Giraffe (*Giraffa Camelopardalis Rothschildi*)

Dr. M. Adil Abbas Khan, Dr. Ammar A. Javed, Dr. Colin M. Morrison,  
Dr. Robert Bains, Mr. Michael Griffith, Ms. Linda Morrison, Dr. Muhammad Riaz

---

## ABSTRACT

We report the use of a random pattern fasciocutaneous flap to cover exposed bone in the hind limb of an 8-month old, hand reared, male Rothschild giraffe (*Giraffa camelopardis rothschildi*) four weeks after a suspected traumatic injury. Under general anaesthesia, a medially based, fasciocutaneous flap was raised, transposed and inset to cover an area of exposed metatarsus. The donor site was resurfaced with an autologous split thickness skin graft harvested from the ipsilateral thigh of the giraffe. The recipient site experienced delayed healing due to an initial wound infection and post-operative management of the flap recipient site involved dressing changes, wound toilet, analgesia and antibiotics. Follow-up showed good flap take providing the animal with stable, durable and functional soft tissue reconstruction.

---

**Key Words:** fasciocutaneous flap, exposed bone, Rothschild giraffe (*Giraffa camelopardis rothschildi*)

## Introduction

Wounds with soft tissue loss and exposed bone in the distal part of a limb frequently require specialist reconstruction. Resurfacing such large complex limb defects can be a challenge in both humans and animals. The initial rungs of the reconstructive ladder involving delayed healing by secondary intention or skin grafting may not be feasible in an avascular wound bed [1]. Pedicled fasciocutaneous flaps for bony cover are well documented in humans and have also been described in small [2] and large animals [3,4]. We describe the successful use of a local fasciocutaneous flap

to cover an area of exposed metatarsus in a giraffe. Also an interesting aspect was the anaesthetic approach taken to operate on a giraffe, particularly given its anatomy with special focus on the long length of the neck

## Case

An 8-month-old, hand reared, male giraffe incurred an injury to the right hind limb below the hock following an unobserved incident. It was suspected that the giraffe caught the limb under a gate and sustained the injury while attempting to free itself. This resulted in a laceration on the cranio-lateral aspect of the limb with soft tissue loss and an area of exposed metatarsal bone. Physical examination and plain radiographs did not reveal evidence of a fracture and the animal showed no signs of discomfort.

The animal was estimated at 150-200kg and all dosages of medications were estimated using a combination of previous doses used in the zoo and recommended dose rates. All resultant calculated doses were thus illustrated as the absolute amount. Medical

**Dr. Ammar Asrar Javed M.D.**  
Lead Postdoctoral Research Fellow and Senior  
Research Program Coordinator  
Department of Surgery, The Johns Hopkins  
School of Medicine,  
600 N. Wolfe St./Blalock 1222A  
Baltimore, Maryland (MD), 21287  
Telephone: 667.208.7086  
Fax: 410.588.6681

wound management was attempted using amoxicillin (Betamox LA, Norbrook UK) and wound dressings. The wound dressings were comprised of hydrogel (IntraSite gel, Smith & Nephew) or petrolatum-impregnated gauze pads (Jelonet, Smith & Nephew), polyester-covered absorptive cotton sheets (Melolin, Smith & Nephew) and/or cotton wool, lightweight conforming bandage (K-band, Urgo) and bandaging tape (3M™ Vetrap™ Bandaging Tape). Bacterial culture and sensitivity testing revealed a resistant *Proteus* species and therefore antibiotic was changed to enrofloxacin (Baytril Max, Bayer UK). After several weeks, there was still no evidence of healing and the soft tissue defect with bony exposure had almost doubled in size (Figure 1)

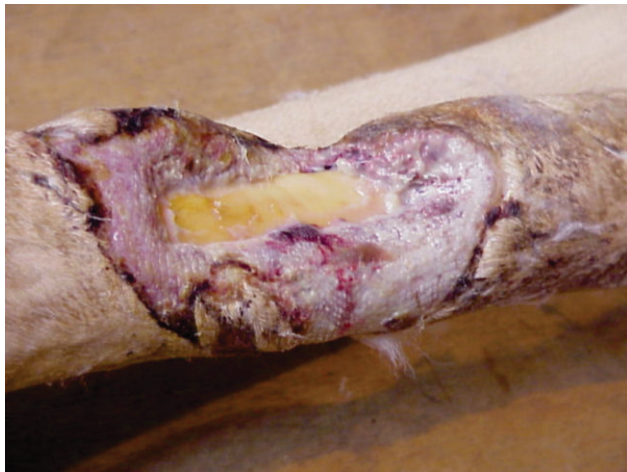

Figure 1: Preoperative photograph of the soft tissue defect before debridement. The exudate overlying the granulation tissue and necrotic wound edges were debrided and the bony cortex minimally burred to expose healthy bleeding bone.

The zoo vets liaised with Plastic Surgeons to avoid euthanasia of the animal by considering surgical management as a last resort four weeks after conservative management failed to heal the wound. Pre-operative assessment included temporary exclusion of the animal from the herd, fresh microbiology swabs, and jugular blood samples which were within normal haematological and biochemical ranges (ISIS December 1999).

### Anaesthesia and Surgical Technique

A general anaesthetic of 9mg sublingual medetomidine (Zalopine 10mg/ml, Orion Pharma, Finland) and 150 mg ketamine (Vetalar-V 100 mg/ml, Pfizer Ltd) was administered by hand injection and then surgical anaesthesia was maintained with the giraffe in left lateral recumbent position, on a makeshift surgical table made of bales of hay (Figure 2)



Figure 2: The makeshift operating table made of bales of hay in the giraffe's enclosure.

using oxygen and isoflurane (Isoflurane-Vet, Merial Animal Health, Ltd) via a 12mm on a large animal Steven's anaesthetic machine using a circle circuit. (Figure 3)



Figure 3: The intubation tube consisting of a long rubber pipe inserted intranasally.

The surgical site was prepped by iodine solution and thoroughly irrigated with saline. Necrotic and infected tissue was debrided, till healthy bone could be visualized. A random patterned, pedicled fasciocutaneous flap measuring 15 x 5cm was raised (wound size 12cmx14cm) from the medial side of the leg (Figure 4).

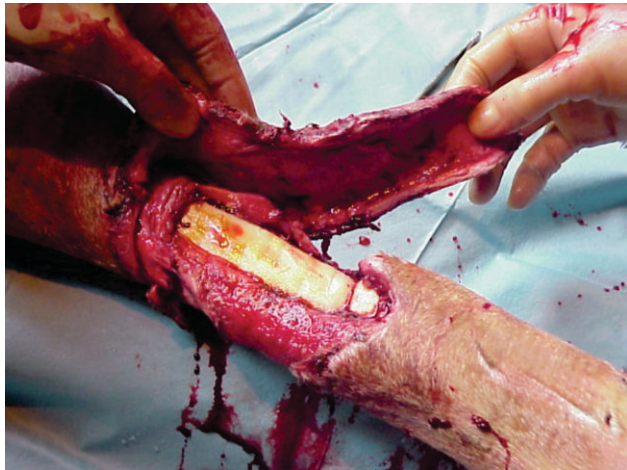


Figure 4: The superiorly based local fasciocutaneous flap harvested from the medial aspect of the hind limb.

Additional circumferential undermining proximally was required to ensure complete wound coverage. The flap was secured with simple interrupted, 2/0 (Polyglactin 910) suture (Vicryl rapide, Ethicon).

The donor defect was resurfaced using a split thickness skin graft, taken with a Humby skin graft knife (Downs Surgical, Sheffield, UK), from the ipsilateral thigh (Figure 5).

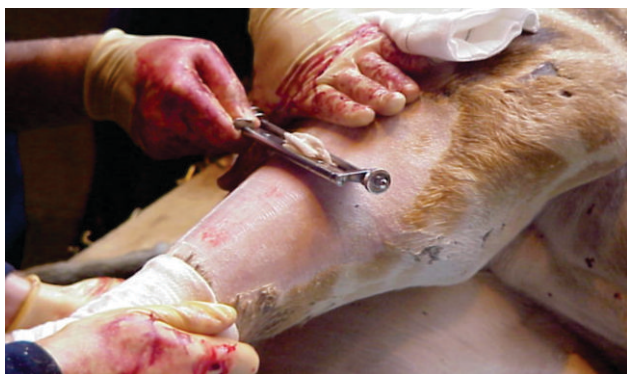

Figure 5: Harvesting the split thickness skin graft with a Humber knife after shaving the ipsilateral lateral thigh

The graft was secured with staples (3M™ Precise™ Disposable Skin Staplers) and the wound dressed with iodine soaked gauze.

Finally, recipient site of the graft was dressed with Kaltostat and Mefix™ (SCA Molnlycke Ltd.), an adhesive retention dressing that is commonly used in humans. Though attempts were made at placing drains at the recipient site it was not possible given the thick and rough nature of the skin. The surgical procedure took 90 minutes after which the anaesthesia was reversed using 45mg of intravenous atipamezole (Antisedan, Pfizer UK) and the giraffe was able to stand unaided after 6mins.

The giraffe was returned to the herd 3 hours later. The Mefix™ dressing became detached from the donor site within the first 48 hours. This wound was left uncovered and healed without complications. Suction drains (Blake Drains™, Ethicon, Inc.) were attempted but were not found to be effective.

The recipient site however required more intensive management. Dressing changes were required every 48 hours initially with an increased inter-dressing interval as the wound gradually closed. Wet to dry dressings and dry dressings using combinations of the materials described above, with the exception of Jelonet, were applied. The dressing change was performed within the holding pens and required an anaesthetic. Medetomidine (as above) and ketamine (as above) were used, while atipamezole (Antisedan, Pfizer UK) was used for reversal. Initially the dressing changes lasted 10 minutes during a total 30-minute anaesthetic period, reducing to 5 minutes during a total 20-minute anaesthetic period. Dressing changes were performed aseptically and the wound was always flushed with copious amounts of sterile saline (Isolec LA solution, IVEX, Larne). 250mg of carprofen (Rimadyl LA solution, 50mg/ml,

Pfizer UK,) was used for 6 weeks post-operatively for both analgesic and anti-inflammatory effects. 750mg gentacin (Pangram 5%, 50mg/ml, Bimeda) was used for 2 weeks post-operatively then 300mg marbofloxacin (Marbocyl 10%, 100mg/ml, Vétquinol UK) and 1500mg enrofloxacin (Baytril Max, 100mg/ml, Bayer UK) for a further 2 months as suggested by culture and sensitivity testing (which was performed every 2 weeks).

Despite these practices, the wound became infected superficially with a mixed bacterial population, including a multi-resistant *Pseudomonas* (sensitive to gentamicin), which led to partial wound breakdown. Systemic antibiotics were stopped as it was suspected that they were contributing to development of resistance rather than effectively controlling infection. Copious wound lavage and regular sterile dressing changes were used to manage the superficial wound infection for a total of 10 weeks resulting in healing. Nine months after surgery, minor trauma to the wound required medical management using dressings as before and antibiotics for 7 weeks. 18 months later the giraffe was re-homed to another zoo. The animal was able to ambulate normally throughout this period (Figure 6).

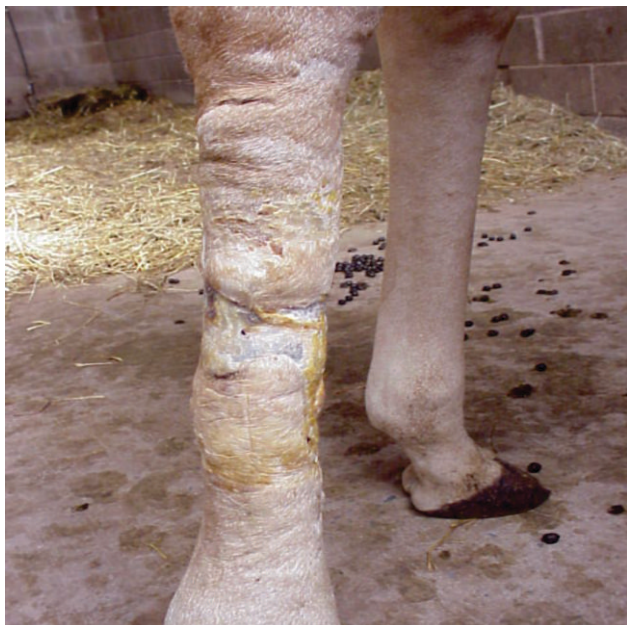

Figure 6: Twelve months post-operative view of the healed fasciocutaneous flap over the giraffe's fully functional and weight bearing right hind limb.

Four years after the initial operation, however, the site of initial flap reconstruction suffered recurrent wound breakdown and infection necessitating the giraffe to be euthanized.

### Discussion

Two aspects of this case need to be discussed in detail; the anaesthetic approach and wound management. Long general anaesthetics in larger animals can pose a significant risk of increasing morbidity or mortality. Complications such as post-anaesthetic paresis or paralysis have been observed. This is a particular problem in the giraffe, with difficulties in airway management and blood pressure control being recognised hazards. In total the giraffe underwent 71 anaesthetics over a period of 11 months. Repeated blood sampling revealed no significant alteration in biochemical and haematological parameters throughout this period. The anaesthetic management of the giraffe in our case was successful and no anaesthesia related complications were experienced. We therefore suggest that in future while performing surgical operations involving larger animals the management we adopted may be considered.

The priorities in surgical wound management are irrigation and debridement of all necrotic tissue, fracture fixation, if necessary, and soft tissue reconstruction. Bone exposure precludes skin grafting, so in many cases local or distant flaps are required. These may be muscle, myocutaneous, adipofascial or fasciocutaneous flaps. Due to the significant anaesthetic risk, in cases where well-equipped operating facilities are not available, shorter, simpler procedures such as local fasciocutaneous flaps are preferable. They provide us with a simple reconstructive

option, involving short anaesthetic time, which is ideal for cases like ours, involving minimal tissue dissection. These flaps can also be raised without requirement of specialist theatre, equipment and can either be based on a known pedicle or vascular perforator or be entirely random patterned. Since the exact microvascular anatomy of the skin in the giraffe has not been described to date, a random pattern pedicle local fasciocutaneous flap we believe is a more feasible option.

The giraffe tolerated the dressings well. Wet to dry dressings and dry dressings were found to be the most effective and easiest to apply. The Mefix™ dressing was presumed to have become detached due to limited adhesiveness to the rough, haired skin of the giraffe. However, dressing interference by herd members may also have contributed. When the wound became infected later in the recovery period, several unsuccessful attempts were made to use a suction drain which we attributed to the thick and rough skin of the giraffe, which made it impossible to maintain the negative pressure required for the drain to work efficiently. Topical cleansing and dressing changes appeared to be more effective than antibiotics in control of wound infection in our case. This may be due to difficulties in assessing an accurate weight for a growing animal and/or possibly altered pharmacokinetics of the drugs in the giraffe. Both the anaesthetics and repeated handling were well tolerated. The animal could be maintained with the rest of the herd during the entire time without interference to the dressing. We believe that this can be attributed to the fact that the giraffe was hand reared.

When managing wounds on larger animals, medical treatment is often the initial

approach, with surgical treatment reserved for animals of significant economic or emotional value. We believe that an earlier intervention would have been beneficial in this case and would have helped in avoiding any of the aforementioned acute and intermediate post-operative complications. Similarly, the final outcome of the animal being euthanized, highlights an important principle that while the reconstruction worked, earlier intervention would have been more appropriate. This view has been already reported for soft tissue reconstruction employing both flaps and grafts, in the equine model as this large animal species is likely to have such procedures done due to its economic value [5]. Our intervention however, managed to give the animal a reprieve of a few years which is significant especially in any large endangered species of high genetic value. In addition, this case has novel value as surgery of this nature has never been previously performed in a giraffe.

In conclusion, a fasciocutaneous flap, performed acutely after injury, is an effective method of reconstructing an extensive soft tissue wound in large animals such as a giraffe. Reconstructive surgical techniques described in man and other animals may be considered useful in the giraffe but further research may still be required to identify optimal approach and treatment. A random pattern fasciocutaneous flap performed with the aforementioned anaesthetic management proved to be effective in reconstructing an extensive soft tissue wound in this animal.

### **Acknowledgements**

We would like to thank staff of Belfast zoo for all their hard work and consistent support.

## References

1. Fix R.J., V.L.O., Fasciocutaneous flaps in reconstruction of the lower extremity. *Clin. Plast. Surg.* , 1991. 18: p.571.2.
2. Skin grafting and reconstruction techniques IN: Bojrab M.J., E.G.W., Slocum B. *Current Techniques in Small Animal Surgery*, 4th Edition, Williams and Wilkins: Chap 37, P585-642.3.
3. Wilson D.G. Applications of skin grafting in large animals, *P.V.M.S.-.*
4. Schumacher J, S.G.I.A.J., Stick J., *Equine Surgery*, Third edition, Saunders+Elsevier: Chapt 25, P269.5.
5. Bristol, D.G., et al., The isolated perfused equine skin flap. Preparation and metabolic parameters. *Vet Surg*, 1991. 20(6): p.424-33.

