

# Intra-neural ganglions of the ulnar nerve: Case report and review of the literature

Mr. Shenbana Bagirathan, Mr. Heidi Jones, Mr. Muhammad Riaz

---

## Summary

We report the case of a middle-aged, male, electrician with a prolonged history of left hand ulnar nerve sensory-motor deficit, intrinsic muscle atrophy, clawing and palpable swelling to his left wrist. This was confirmed as an intraneural ganglion of the ulnar nerve on ultrasonography and magnetic resonance imaging.

Our literature review highlights that intraneural ganglions of the ulnar nerve can occur more frequently than once thought, particularly in middle-aged men, who may or may not have a previous history of local or regional trauma. The duration of symptoms is a predictor of the likelihood of recovery. Surgical excision remains the mainstay of treatment and is usually curative, but must be performed as soon as possible if the patient is to achieve resolution of their symptoms. The longer it is left, the longer the course of recovery. We recommend that clinicians have a high index of suspicion of intraneural ganglions when faced with progressive ulnar nerve compression neuropathy and/or a palpable swelling along the course of the nerve.

---

*Key Words: ulnar nerve, ganglion.*

## Introduction

Ganglions are benign mucinous cysts commonly associated with joint capsules, tendons and tendon sheaths. Intraneural ganglions are those found within the epineurium of a peripheral nerve<sup>1,2</sup>. The first case was reported in 1901 and has since frequently been described as occurring in the peroneal nerve at the fibular neck region<sup>1,2</sup>. In the upper limb, they most commonly occur in the ulnar nerve<sup>3,4</sup> and are not as rare as once thought. We report the case of an ulnar nerve ganglion arising in Guyon's canal and review the literature surrounding these benign lesions, which can cause profound functional disturbance in the individual if left untreated.

We present a case report to describe common presentations and the management of these ganglions.

## Case Report

A 61-year old, male, right hand dominant electrician presented with a one-year history of left hand weakness, and three-year history of left hand pain and numbness. He had a five-month history of a swelling to his left wrist volar surface. He also had a history of a left hand injury twelve years previously which resulted in an ulnar nerve injury that spontaneously resolved. On examination, he had clawing of his left hand, severe atrophy of the interossei and hypothenar eminence, and reduced extension of the ring and little fingers. He had paraesthesia of the little finger volar surface and there was a palpable, fluctuant swelling on the ulnar-volar aspect of his wrist. An ultrasound scan revealed a mass suggestive of a large ganglion, 3.2 x 1 x 2.1cm, involving the deep motor branch of the ulnar nerve which was confirmed by MRI located in Guyon's canal (figures 1 & 2).

**Mr. Shenbana Bagirathan**

*Plastic Surgery Registrar*

*Department of Plastic Surgery, Hull & East  
Yorkshire Hospitals NHS Trust Castle Road,  
Cottingham HU16 5JQ, United Kingdom*

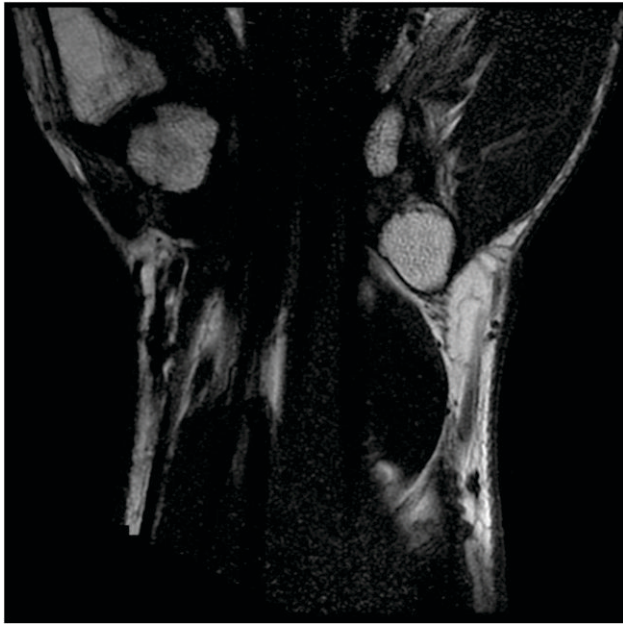


Figure 1. *T1-weighted magnetic resonance image of patient's ganglion within Guyon's canal*

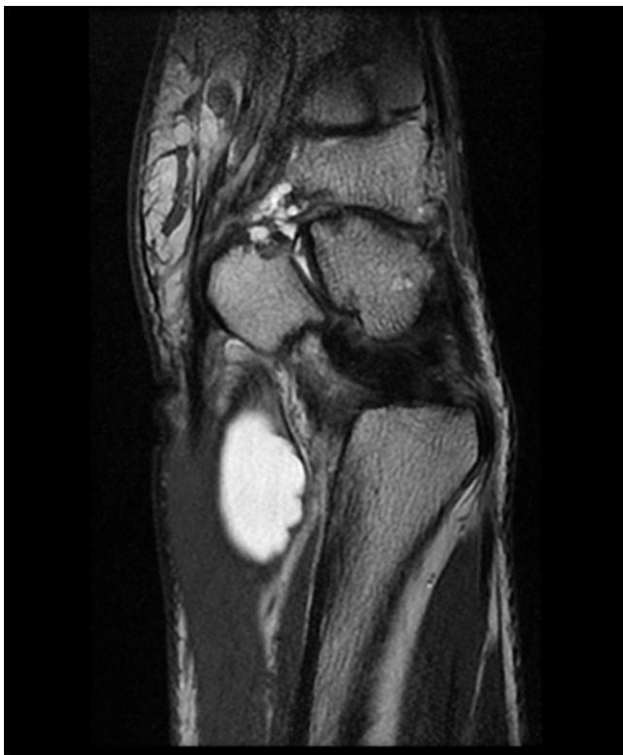

Figure 2. *T2-weighted magnetic resonance image of patient's ganglion within Guyon's canal*

Nerve conduction studies showed a distal ulnar nerve lesion only causing denervation of the small muscles of the left hand, and excluded peripheral neuropathy.

The patient underwent an urgent intraneural

dissection and excision of the ganglion from his left wrist ulnar nerve. Intra-operatively, a volar-ulnar incision was made and a densely adherent intra-neural ganglion was identified within the epineurium of the ulnar nerve in Guyon's canal (*figures 3-5*).

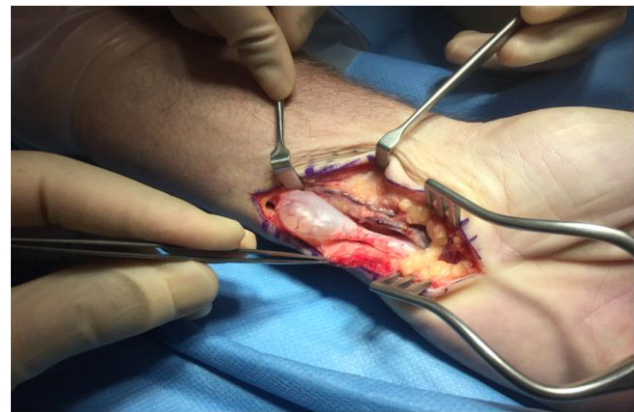

Figure 3. *Intraneural ganglion within left wrist Guyon's canal*

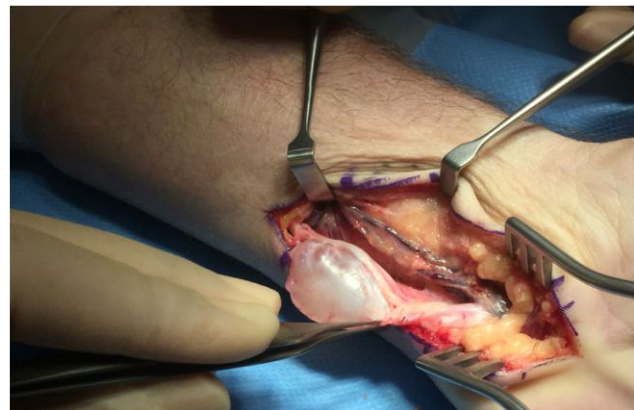


Figure 4. *Ulnar nerve epineural ganglion within Guyon's canal*

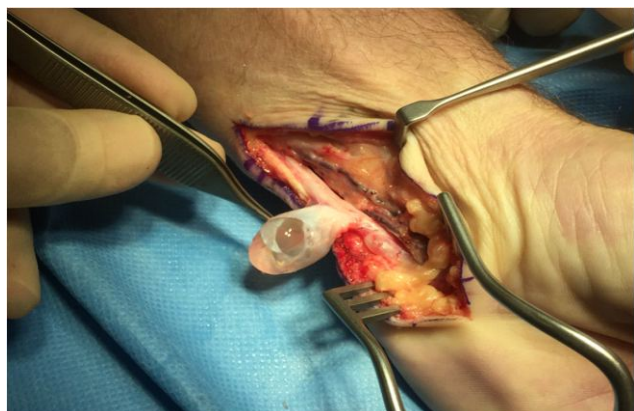


Figure 5. *Densely adherent ulnar nerve epineural ganglion*

The ganglion measured 5cm in length (figure 6) and the ulnar nerve was flat and inflamed (figure 7).

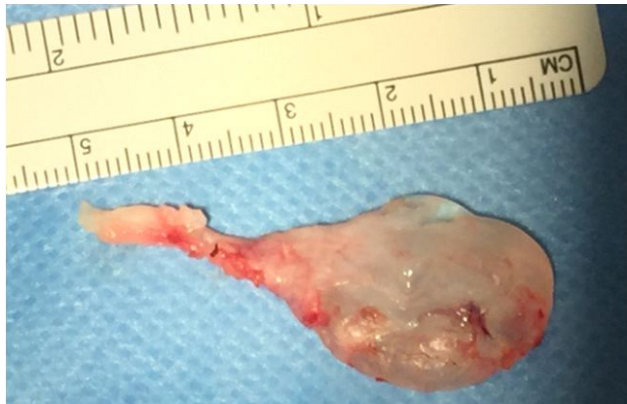

Figure 6. Intra-neural ganglion following excision from left ulnar nerve, measuring 5cm in length

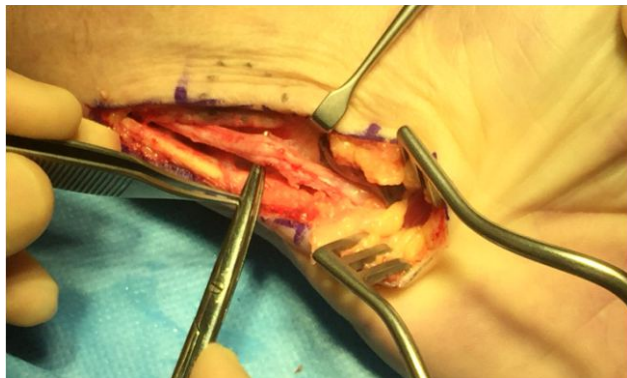


Figure 7. Flat and inflamed left ulnar nerve within Guyon's canal, following excision of ganglion

Histological diagnosis confirmed a benign ganglion. At three-month post-operative follow-up, he continued to have weakness in his left hand with persistent small muscle atrophy (figures 8-10).

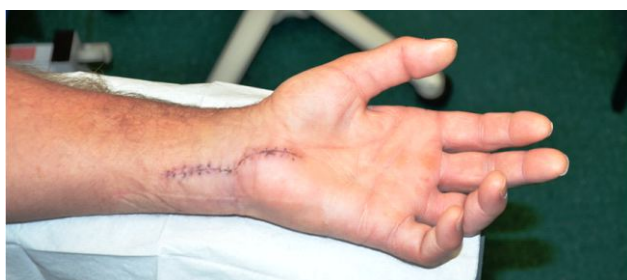

Figure 8. Hypothenar wasting & clawing of left hand at 1-week post-op

Figure 9. Continued hypothenar wasting at 3-month follow-up

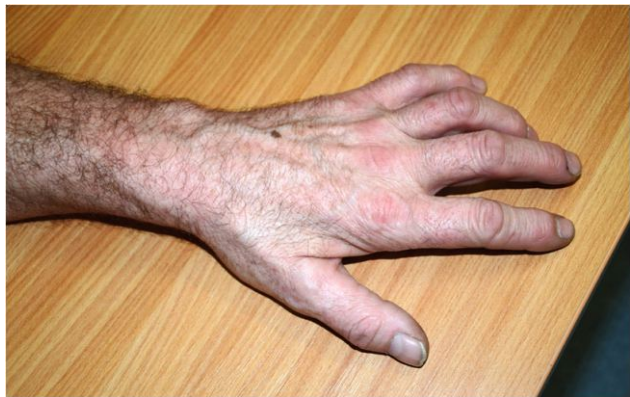
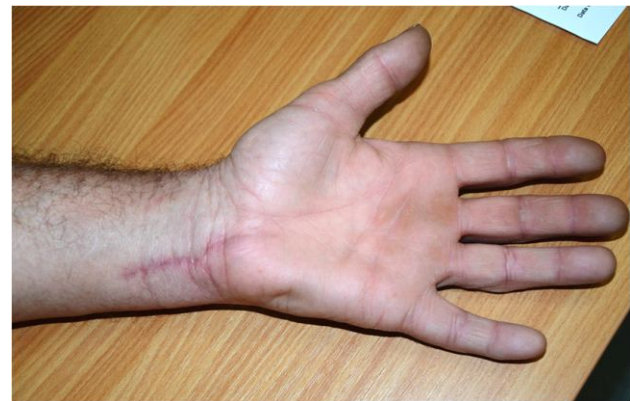
Figure 10. Intrinsic muscle atrophy of left hand at 3-month follow-up

However there was no evidence of ganglion recurrence.

### Discussion

Intra-neural ganglions were previously reported as rare and occurring more frequently in the common peroneal nerve, however following a review of the literature we believe these cases are more common than expected in the upper limb, often affecting the ulnar nerve. Kato et al describe a series of 38 patients with ulnar nerve compression at the elbow, 8% were secondary to ganglia, all originating from the ulno-humeral joint capsule<sup>6</sup>. Wang et al went on to report 60 cases of intra-neural ganglions of the ulnar nerve, of which 22 were at the level of the wrist, and 3 had joint connections<sup>5</sup>. Naam et al reviewed 15 patients with intra-neural ganglia of the hand and wrist, of which almost half were involved in the ulnar nerve at the wrist or the dorsal branch of the nerve<sup>4</sup>.

Allieu et al state that intraneural ganglia most commonly affect middle-aged men, particularly those with a history of trauma<sup>6</sup>. Our patient was within this group of patients, however was unable to recall the exact mechanism of his previous injury. We identified seven case reports of ulnar nerve intraneural ganglion at the elbow or wrist, five male and two females; five patients between the age of 40 to 51 (age range 25-73, mean 46.4 years old). Of these, four patients had previous trauma, either locally or regionally. Naam et al also reported a mean age of 42 years old in their case series of intraneural ganglions of the hand and wrist<sup>4</sup>. Our patient presented with classical symptoms and signs of compression neuropathy of the ulnar nerve. This is in keeping with all the cases of ulnar nerve intraneural ganglion regardless of proximal or distal lesions, however not all cases presented with a palpable localised swelling. Therefore those patients presenting with compression neuropathy at the elbow were often mistaken as a simple cubital tunnel syndrome.

Intraneural ganglions remain poorly understood, however two theories exist around their pathogenesis. Historically, they were thought to be the result of repetitive microtrauma causing mucoid degeneration of fibrotic tissue<sup>3,7</sup>. More recently, Spinner et al suggest that a joint connection into the peripheral nerve exists via an articular branch in all intraneural ganglions<sup>8,9</sup>. The significance of the latter relates to the method of surgical excision, which we will discuss later in this review article. Investigation tools are particularly useful in patients where a mass is not palpable and no clear diagnosis has been reached. These include electrophysiological studies, ultrasonography and magnetic resonance imaging (MRI). MRI allows for demonstration of the cystic nature of the mass, anatomical location and its extension, beneficial for pre-operative surgical planning. Typically they appear as a

juxtaneural uniform cystic lesion, often multi-locular that are hypointense on T1-weighted images (*figure 1*) and hyperintense on T2-weighted magnetic resonance images<sup>10</sup> (*figure 2*). Spinney et al described several consistent features on MRI, which characterised intraneural ganglions and include a relatively narrowed neck (tail sign), tubular appearance because of its confinement within the nerve, balloon-like expansion (balloon sign) wherein fascicles are displaced by the cyst (signet ring sign)<sup>8-10</sup>.

Benign and malignant tumours, such as malignant peripheral nerve sheath tumours, must be distinguished. It is important to consider the latter as a differential diagnosis in patients presenting with upper limb peripheral neuropathy. Mobbs et al described that two or more of the features on MRI were 90% specific for a malignant diagnosis which include large size, indistinct margins, abnormalities in adjacent soft tissue, peripheral enhancement pattern, lack of contiguity with adjacent nerves<sup>7</sup>.

However, these features may not always be present, and may only be diagnosed intra-operatively<sup>5</sup>.

The mainstay of treatment in all cases has been surgical excision of the ganglion, which may be performed in one of three ways. We performed dissection of the ulnar nerve and intraneural excision of the ganglion, as described by Naam et al<sup>4</sup>. However, the unifying articular theory of intraneural ganglions infers that for successful elimination, the articular branch must be excised and the ganglion itself can be simply drained or decompressed. In our case, careful exploration of the nerve and ganglion were performed but no intra-articular branch was identified. In a select number of cases, it may be necessary to excise the ganglion and ulnar nerve, for which nerve grafting may be required. In these cases it is important to discuss beforehand with the patient, as well as counsel him/her to the possibility of limited

recovery of normal limb function. Naam et al reported that neither of these three methods of surgical treatment had complications or recurrence; symptoms improved in all patients and all patients returned to normal activities at a mean ten days<sup>4</sup>. In fact, patients with a prolonged duration of symptoms had a slower return to normal function and persistent residual symptoms, secondary to stretching of the nerve<sup>1,3</sup>. At three months, our patient continues to have left hand weakness and small muscle atrophy, which may be consequential to his prolonged symptoms and size of the ganglion. We plan to continue his follow-up every six-months.

### Conclusion

The intraneural ganglions of the ulnar nerve are not as rare as previously described. We recommend clinicians to have a high index of suspicion and to include intraneural ganglions in their differential diagnosis when a patient presents with signs of ulnar nerve compression and/or a swelling anywhere along the course of their ulnar nerve. The surgical excision tends to be curative and the mainstay of treatment.

### References

1. Sinha S, Pinder RM, Majumder S. The largest reported epineural ganglion of the ulnar nerve causing cubital tunnel syndrome: Case report and review of the literature. *J Plast Reconstr Aesthet Surg* 2013;**66**(1):e23-5.
2. Chen WA, Barnwell JC, Li Y, Smith BP, Li Z. An ulnar intraneural ganglion arising from the pisotriquetral joint: case report. *J Hand Surg Am* 2011;**36**(1):65-7
3. Wang H, Terrill RQ, Tanaka S, Amrami KK, Spinner RJ. Adherence of intraneural ganglia of the upper extremity to the principles of the unifying articular (synovial) theory. *Neurosurg Focus* 2009;**26**:E10,1-9.
4. Naam NH, Carr SB, Massoud AH. Intraneural ganglions of the hand and wrist. *J Hand Surg Am* 2015;**40**(8):1625-30
5. Kato H, Hirayama T, Minami A, Iwasaki N, Hirachi K. Cubital tunnel syndrome associated with medial elbow ganglia and osteoarthritis of the elbow. *J Bone Jt Surg Am* 2002;**84-A**(8):1413-9
6. Allieu PY, Cenac PE. Peripheral nerve mucoid degeneration of the upper extremity. *J Hand Surg Am* 1989;**14**(2 Pt 1):189-194
7. Mobbs RJ, Phan K, Maharaj MM, Chaganti J, Simon N. Intraneural ganglion cyst of the ulnar nerve at the elbow masquerading as a malignant peripheral nerve sheath tumour. *World Neurosurg* 2016;**96**:613.e5-613.e8
8. Spinner RJ, Desy NM, Amrami KK. Sequential tibial and peroneal intraneural ganglia arising from the superior tibiofibular joint. *Skeletal Radiol* 2008;**37**:79-84.
9. Spinner RJ, Desy NM, Rock MG, Amrami KK. Peroneal intraneural ganglia. Part I. Techniques for successful diagnosis and treatment. *Neurosurg Focus* 2007;**22**:E16, 1-10.
10. Spinner RJ, Amrami KK, Angius D, Wang H, Carmichael SW. Peroneal and tibial intraneural ganglia: correlation between intra-epineurial compartments observed on magnetic resonance images and the potential importance of these compartments. *Neurosurg Focus* 2007;**22**:E17, 1-10.

